Dr. Narla Unbreen

HIV guidlines by Dr. Ehtesham

when HIV was 1st detected → 1981 imp
3yrs later in 1983 → AIDs is identified.
⇒ HIV is a RNA virus.
⇒ Difference b/w HIV +, AIDS +ve
HIV +ve means HIV testing +ve. (HIV antibodies +ve)
In HIV pt. if either CD4 < 200 cell/ul or CD4 lympho cytes % is <14% it is AID or opportunistic infec. tion (aids defining illness).

Diagnostic criteria of AIDs
Definitive AID without ↑ with laboratory evidence
Definitive AID with laboratory evidence.
presumptive AIDs Diagnosis

Table 33-1.
CMDT.

Modes of transmission
Sexual >
parentral >
vertical.
Most common route is sexual. and highest amongst receptive anal.

pathophysiological mechanisms of AIDs.
3 mechanisms
1) Immunodeficiency. HIV virus directly attacks immune cells causing immunodef.
2) Autoimmunity :. Immune cell dysfunction & auto antibodies.
3) Allergy & hypersensitivity.

Forms of HIV 2 forms
HIV I HIV 2

Dr. Naila Unbreen

HIV I is found worldwide 10 ~~subtypes~~ (genotypes of HIV 1 most common genotype M.
HIV 2 :- less virulent found in south africa. Same mode of transmission but low rate of transmission & slow progression to AIDs.

work up of HIV

1- ⇒ 1 :- 4th generation ~~test~~ HIV I & II antigen antibody immuno assay.
it detects antibodies against both HIV I and HIV 2 + also detects HIV I P24 antigen
if This test is +ve →
⇒ HIV I & 2 antibody differentiation immuno assay (Multi spot immuno assay) HIV confirmatory test
if +ve → Diagnosis confirmed → start HIV treatment.

2 ⇒ if both are -ve:
if 4th generation HIV I & II antigen antibody immuno assay -ve and suspicion is high and you do HIV I and 2 antibody differentiation assay its also negative → pt may be in window period and has not formed antibodies yet.
(Suspicion on basis of unscreened blood transfusion/ high risk sexual behavior etc)
then go for viral load by PCR. RNA HIV.
Nucleic acid test or HIV I viral load test.

3 ⇒ if Result inconclusive → antigen antibody assay +ve but antibody differentiation immuno assay -ve. →
HIV I viral load test.

If < 1000 /ml. copies → result false +ve
> 1000/ml copies → Significant (Acute HIV inf.)

Y HIV I viral load not HIV 2:.
found all over world, it is more common 10 genotypes. more virulent. more chances to go to AIDs.

=> 4th generation test only detects HIV inf with in 6 weeks after inf in 99% cases. atleast median time is 2 weeks.
It will miss HIV so viral PCR is done.

cause of false +ve HIV RNA PCR..
recent influenza vaccine
Autoimmune / collagen disorder
Allo antibodies in pregnancy.

Screening test for HIV: HIV rapid anti body test. done by blood, gum swab.
result come in 10-20 min. sensitivity & specificity is high for ch. Infection >99%.
when ever screening test +ve → always confirm by standard test (antigen antibody immuno assay or multispot immuno assay).

HIV I viral load
measures amount of actively replicating virus
Used to diagnose acute HIV infect / virus.
so if ⊖ HIV I II antigen immunoassay -ve
differentiation immunoassay -ve
or result is inconclusive
in all these cases offer HIV viral load test.

2- ≤ 500 >350 latent stage)
3- < 350 >200 4- < 200 (severe dis/AIDs)
(Moderate disease)

Dr. Naila Unbreen

Significance

Most accurate indicator of HIV I viral activity
Used to monitor response of antiviral therapy
In acute inf (during window period) we can detect virus

Absolute CD4 lymphocyt count and CD4 lymphocyte %age.

best test to determin stage of HIV inf are
1) absolute CD4 lymphocyt count
2) CD4 lymphocyte percentage.

If CD4 count is <200 cell without treatment
There is ↑ed risk of AIDS opportunistic infections & malignancies
CD4 count is also used to check response of ART treatment
CD4 count is most widely used ~~tool of~~ prognostic tool for oportunistic infection
CD4 percentage is <14% without treatment → ↑ risk of AIDs oportunistic Inf + Malignancy
CD4 count % is more reliable than absolute CD4 count

Qs Screening test for HIV :- Rapid antigen testing
⇒ Confirmatory test:. 4th generation
Multispot immunoassay
⇒ Acute HIV infec test → HIV viral load (PCR)
⇒ Test to assess HIV virus activity:→ HIV viral load test
⇒ Test to check ART response → HIV viral load (PCR)
CD4 count

Dr. Naila Unbreen

⇒ which test will detect acute HIV inf during window period: → HIV I viral load (PCR)

⇒ Test for staging of HIV inf :- absolute CD4 count
CD4 percentage.

Other tests.

CBC : Anemia leucopenia (lymphopenia) thrombocytopenia

ESR. ↑ maybe.

Immunoglobin :- polyclonal hypergammaglobulinemia

hypercholesterolemia in lipid profile

CD4 count every 3-6mnth (CD4 count trend).

BP CBC LFT's RFT's pregnancy test. Baseline viral load + CD4 count.

relationship of CD4 count & opportunistic inf. and Malignancy.

< 500		
Bacterial inf		
TB		
HSV.	< 300	
Herpes zoster.	pneumocystosis	
Vaginal candidiasis	Toxo	
(EBV) Hairy leukoplakia	Cryptosporidiosis	< 50
(HHV8) Kaposi sarcoma	Cryptococcosis	Disse. MAC.
	Coccidiomycosis	Histoplasmosis
		CMV retinitis
		CNS lymphoma

WHO staging of HIV. 1 to 4. (acc to CD4

1. Asymptomatic or flu like symptoms + lymphedenopathy
CD4 count ≥ 500
2. ≤ 500 > 350 latent stage)
3. < 350 > 200 4. < 200 (severe dis/AIDs)
(Moderate disease)

CamScanner

Dr. Naila Unbreen

prevention of HIV

- Safe sexual practice
- use of condoms
- HIV screening as soon as possible
- ART prophylaxis
- Screening of blood before transfusion

⇒ Pre exposure prophylaxis of HIV. (who want to do sex with HIV positive or want to share needles with HIV + person and to transgenders and bi-sexuals.

Tenofovir Disoproxil + Emtricitabin.
300mg Fumarate 200mg.
1 x OD

- Truvada
- Ricovir-em.
- Discovi Entricitabin + TAF 200 + 25mg.

If only once sexual contact → do testing of HIV after 6weeks → if -ve then stop treatment
If continues sexual contact → life long treatment

⇒ Post exposure prophylaxis

some 1 get needle prick, unscreened blood transfusion, after sexual contact with HIV +ve, ~~###~~ to I/V drug. 0.6%. Blood donor HIV. 93%. needle prick: 0.3% (HCV 3% HBV 30%)

start post exposure prophylaxis with in 72hrs for 4 ~~4 hrs~~ weeks. best is to start with in 6hrs. no use of prophylaxis after 72hr. This is done in HIV clinics.

Immediate do HIV testing to see either pt is already HIV +ve or not - for baseline record

Dr. Naila Unbreen

Acriptiga 50/300/300 Dolutegravir/Lamivudin /TDF
for 1 month
or TDF + Emtricitabin 300/200 OD.
+ Reltegravir 400 BD preferred combination

after 1mth HIV antibody testing — if -ve stop treatment
if +ve → continue tx → repeat testing at 3mnth and 6mnth.

Pregnancy & HIV.

vertical transmission (perinatal transmission)
without treatment 13-40% risk
If ART started <1%

All preg women should screen for HIV.
All preg women who are diagnosed as a case of HIV should be started on ART during preg. regardless of viral load or trimester of preg. when you start ART it will reduce the risk from 40% → <1%.

Zidovudin lamivudin, Ritonavir boosted lopinavir
Efavirins is teratogenic
Dolutegravir is also teratogene

Mode of delivery: if PCR load of mother >1000copies go for C-section
If viral load unknown → C-section
if <1000 copies on PCR → we can opt NVD still c section is superior.

Baby:
Baby also needs prophylaxis for 6 months
Syp Zidovudin 10mg/5ml.

Breast feeding:
If mother HIV infected avoid breast feeding to baby and use formula milk.
but if mother on ART → she can breast feed her baby

Risk of HIV transmission by various routes

Needle prick injury.	0.3% (1 in 300)
I/V drug abuse	0.63%
Unscreened donor blood	93%

In all such cases post exposure prophylaxis

Imp
Saliva sweat tear, stool respiratory droplet and mosquito do not transmit HIV. They are not infectious.

Surgeons with HIV
Surgens viral load PCR.
If < 200 copies → he can perform surgery or invasive procedure.
> 1000 copies → Not allowed to perform surgery.

Blood Donation by high Risk personals.
Don't allow blood ~~transfusion~~ Donation by high risk personels i.e I/V drug abuse, high risk sexual behavior, ~~viral load PCR.~~

If he wants to donate, first do viral load PCR if -ve then we can consider. otherwise don't allow.

Vaccine:

Vaccine in clinical trials is alvanaxypox.

2 inj are given but efficacy is only 31%.

how long will it take to develop AIDs from Inf.

All seed +ve individuals who are HIV +ve in almost 10yrs they are converted to AIDs

HIV & TB

Do screening with PPD or Igra.

Igra by Quantiferon or T-spot

Significant PPD in HIV = ≥5mm. induration

If PPD or IGRA + → Do chest x-ray

If x-ray is +ve → treat active TB

If x-ray is -ve → latent TB → treat latent TB.

⇒ If CD <200 PPD is false +ve

So 1st start ART and bring CD4 count above 200 and then repeat PPD or IGRA

Treatment of HIV and TB co-infection

In All HIV pts do screening for TB & vice versa.

If HIV pt is taking protease inhibitors or integrase inhibitor as ART. replace rifampicin with Rifabutin in ATT.

⇒ If Rifabutin is not available then replace protease or integrase inhibitor with ritonavir boosted lopinavir

Dr. Naila Unbreen

⇒ 1st start ATT. If there is a pt. with coinf. after 2-8 weeks start ART to avoid IRIS (Immune reconstitutional Inflamatory syndrom). If still IRIS occur → treat it with steroroids. and conti ART unless some life threatning condition

⇒ continue ATT for 8 mnths.

⇒ continue ART ~~for~~ until tx response of HIV achieved or life long.

What is tx response of HIV

undetectable viral load consistenlly for 3 conseq months

. Once tx response is achieved then stop ART with cont. monitoring if viral load ↑es restart ART.

. If tx response not achieved → cont. ART. lifelong.

Treatment of HIV with MDR TB.

Bedaquiln + Pretomanid + Linzolid based regimen is famous but you can select any drug tx. Bedaquiln has interactions with protease Inhibitors. Either do close monitoring or ART without protease Inhibitor regimen

HIV + HCV Coinfection

Sofos + ladipasvir ~~is~~ for 3mnths after start ing ART. and avoid Daclatasvir (it has interactions with ART)

HIV + HBV co infection.

Start ART regadless of CD4 count. Tenofo. -vir based. i-e TDF + Emticitabin

TAF + Emticitabin

TAF + Lamivudine

Dr. Naila Umbreen

TDF + Lamivudin

Triple regimen :- Tenofovir + Lamivudin + Dolutegravir
DF
(Acriplega)
for life long.

What is prophylactic tx. offered to HIV or AIDs Pts.

1) pneumocystis carini pneumonia (PCP) prophylaxis
- if CD 4 count < 200.
  Tab septran DS 800/160 thrice weekly to once daily.

and continue untill CD4 count is ≥200 for 3 conseq months.
- Dapsone.
- Atovaquin
- Aerosolized pentamidine.

2) Toxoplasmosis
if IgG antibody + for toxo Gondii & CD4 <100
Tab septran DS 800/160 once daily and conti until CD 4 count is ≥100 for 3mnths

3) MAC.
If CD count < 50
Tab Klaricid 500 mg BD.
Azomax 1200mg. every weeks
Conti until CD 4 count ≥50 for 3mnths

HIV and Anemia:

Erythropoietin:- if erythropoitin level <500 give inj epokin s/c thrice week.
RBC transfusion

Dr. Naila Unbreen

HIV + Neutropenia:

Give colony ~~factor~~ forming unit growth factor
Inj filgrastin S/c 5ug/kg/week.

=> Live vaccination are not allowed i.e
- Yellow fever
- BCG
- Oral polio
- Oral typhoid.

Classification of ART in 8ps.

1) NRTI (Nucleoside Reverse transcriptase Inhibitor.
   - Emtricitabin
   - Zidovudin
   - Lamivudin
2) Nucleotide Reverse transcriptase Inh.
   - TDF
   - TAF
3) NNRTI (Non nucleoside reverse transcyptase Inh.
   - Efavirense
   - Nivarapine
4) Protease Inhibitors
   - Ritonavir
   - Lopinavir
   - Atazanavir
5) Entery Inhibitors.
   - Enfuvirtide
6) Integrase Inhibitor
   - Dolutagravir
   - Raltegravir
   - Cabotagravir
7) Entery/~~inte~~ and fusion Inhibitor. } new drug
   - ibelizumab.
8) Attachment Inhibitors } N. newer drug
   - Fostemsavir

ART side effect

Zidovudin — Lipoatrophy
Cytopenia (Anemia, thrombocytopenia)

TDF — Nephrotoxic loss of bone mineral density.
so not good in renal compromise and eGFR monitoring)
Also fluid retension (not given in HF

Lamivudine:- In heart failure try to avoid as causes fluid retension

Efavirenze :- Neuropshycological side effect.
Not given in epilepsy & is teratogenic.

protease Inhibitor :- not given in renal stone.

Didanosine :- pancreatitis

Dolutegravir :- teratogenic

⇒ No ART is contraindicated in CLD
In CKD avoid TDF
In preg avoid efavirense and dolutegravir
In HF avoid TDF and Lamivudine

Empirical treatment regimen of HIV

1. start ART as soon as possible irrespectable of acute phase of HIV or CD 4 count. once diagnosis is made!

In PaK Acriptega DOlu/TDF/~~Emtrici~~ Lam
TDF / Emtricitabin

Tenofovir + Emtricitabin or
Lamivudin + dolutagravir/raltegravir/Efavirenz/Nivacapin

⇒ If <12yr of age, breast feeding, pregnant, or TB pt.
We can't give dolutagravir so we give Lamivudin + Nivacapin + Tenofovir.

How we make regimen
2 NRTI's + add 1 other (NNRI/protease inhibitor, integrase inhibitor, entery inhibitor. etc)

Monitoring of HIV pt on ART for treatment Response
Prior to ART start we do BP, CBC LFT RFTs pregnancy test, viral load baseline CD4 count
when pt. on ART to check response we do HIV viral load or CD4 count or both
protocol of monitoring:-
prior to ART, after 2 weeks.
after 8 weeks, every 3 to 6 months
HIV viral load or CD4 count or both to monitor response.

Goal:
Virological supression below or at limit of detection of assay.

Recent or Latest advances in ART.
currently we are giving 2NRTI and 1 other drug.
but now after 2021, 2 new drugs regimen but are nd given to every one

Viral load < 5lac
Viral load suppressed for atleast 6mnths and no HBV confection then we can conti 2 drug based regimen other wise 3drug regimen
2 drug regimen are.
1) Dolutegravir + Lamivudin
2) Dolutegravir + Rilpivirin JULUCA.
3) Carbotegravir I/M once monthly + Rilpwirin
Integerase Inhibitor NNRTI

New drug.
Obelizumab. → MDR and HIV co-inf

Brand Names. available in Pak
Aciplega Viripil
JULUCA
Truvada

Complications of HIV & treatment
1) Wt loss wasting in HIV pt.
This is d/t ↓ apetite, malabsorption, ↑ metabolic rate, recurrent vomiting
start ART. (most effective tx)
for ↑ apetite . Megesterol acetate → liquid suspension form 400 - 800 mg daily in divided doses
. Dronabinol. 2.5-5mg / oral TDS
to ↑ body mass :- growth hormone + anabolic steroid
2) Nausea in HIV
Metochlopramide 10mg ×TDS
Prochlorprazine 10mg TDS
Ondensetrol 8mg TDS
Dronabinol 5mg TDS
& R/O Addisons disease and depression

Dr. Naila Unbreen

Pneumocystic carini pneumonia:

fever, exertional dymea, dry cough

Non specific symptoms

Ix :- • chest x-ray: to look diffuse b/L interstitial Inf.
- illrates + perihilar infiltrates

• Sputum studies: we have to induce sputum as dry cough.

8hr fasting then Neb 3% hypertonic saline or bronchoalveolar lavage.

Done via Weight giemsa stain or sputum direct florescence antibody test or sputum PCR.

• LDH S/ beta glucan test
• ABG's } sometimes
• CT chest as well. } req

treatment:

Trimethoprim Sulphamethoxazole (cotri)/or septran DS: 800/160 mg TDS for 21 days
+ steroids if indicated.

whenever we add steroids, add within 72 hrs. cz within 72 hrs it helps in sing alveolar Inflammation but once indicated

Indications

PaO_2 < 70mmHg.
A-A O_2 gradient. ≥ 35mmHg
saturation < 93%.

how prednisolone 40mg BD from day 1-5
then 40 mg OD day 6-10
20 mg OD daily from day 11 to 21

If can't take orally then methyl prednisolone

or
• Pentamidine with/without steroids.

=> Toxoplasmosis.
CD 4 < 200
toxoplasma serology - IgG antibodies +ve.
For CNS toxoplasmosis → CT-scan e- contrast multiple ring enhancing lesions.
MRI brain with contrast → If CT. scan e- contrast is showing single ring enhancing lesion we will go for MRI brain e- contrast otherwise make diagnosis on CT. scan alone
If MRI brain also shows single lesion then 2 options
1) either give 2 courses of antibiotics and followup MRI brain e- contr
2) or SPECT scan (Cz D/D lymphoma)
=> If SPECT scan uptake ↑ → lymphoma.
uptake ↓ → toxoplasmosis

Treatment
Pyrimethamine + Sulphadiazine + Leucovorin
200mg stat 1g PO QID. 10-25mg PO daily
50mg daily
for atleast 6weeks or CD4 count normalizes
others
Septran DS 800/160 BD for 6week
or Spiramycin.

=> CNS lymphoma
CT-scan brain or MRI brain e- contrast show sigle ring enhancement
SPECT scan show ↑ uptake
also brain biopsy.

Tx :- Dr. Naile Unbreen

Chemo/or Radiatherapy + intrathecal methotrexate + Dexamethasone

Cryptoccocal meningitis

Investigation : +ve latex agglutination test or +ve Indian Ink stain.
or CSF culture for cryptococus.

tx :-
I/V amphotericin B + flucytosine for 2week
then oral fluconazole 400mg for 2 months
then oral fluconazole 200mg OD for 1yr.

CMV retinitis

Occurs when CD 4 count <50
we do fundo & look for characteristic changes.
perivascular hemorhages + white exudates

best tx is oral valgancyclovir 900mg BD with food for 21days followed by 900mg OD for continues as maintainance dose.
If sight threatning (i-e involvment of macula or optic Nerve) add intravitreal gancyclovir 2mg for 7-10days, or foscarnet intravitreal 2.4mg. 1-4doses/day for 7-10days.

Oral candiasis :-

oral fluconazol 50-100mg OD for 3-7 days

esophageal candidiasis

fluconazole 100-200mg OD for 14-21day

Enterocolitis

enteritis in HIV → salmonella
colotis → clostridium dificille

If CD ≤ 200 cryptosporidium causes enterocolitis
If CD < 50 MAC causes enterocolitis
tx of enteritis in HIV:-
~~Foscarnet~~ ART.
Diphenoxylate e- atropine
Octreotide
Colonoscopy e- biopsy if stool culture -ve

Tx of HSV:-
Oral acyclovir 400mg TDS for 5-10day

Tx of varicella zoster.
Oral acyclovir 800mg 5 times a day for 7days.

Common cancers in HIV
① kaposi sarcoma ② non hodgekin lymphoma (diffus large B cell)
③ CNS lymphoma
④ Invasive cervical CA

Kaposi sarcoma tx:
ART + chemotherapy (Doxorubicin Bleomycin Vincristine DBV)

Vaginal candidiasis in HIV Cap fluconazole 200mg daily for 7 days.

Screening for Invasive cervical CA.
1) If female ≥30 or bgyond 60yr. 2 screening Method.
i) cytology with PAP smear once yrly for 3year. If -ve then 3yrly.
ii) PAP smear with Human Papilloma virus DNA testing.
2) If female <30yr. PAP ~~yrs~~ smear ~~after~~ within 14days of sexual activity then 1yrly for 3yrs and if it is -ve then once every 3yrly.

No need of human papilloma virus DNA testing

IRIS :-

once we start ART there is worsening of typical as well as atypical symptoms of HIV. 2 types of IRIS.

Type I :

Typ I is called unmasking flare up of previously undiagnosed inf after ART

Type II :

Typ II is called paradoxical reaction. worsening of previously treated infection after ART.

Diagnosis

Clinical diagnosis. Diagnosis of exclusion.

No investigation

treatment

Conservative tx e- steroid. and ART is continued unless life threatening condition.

HIV & SYPHLIS

we do Rapid plasma reag (RPR) or VDRL every 6 monthly. If +ve start tx with

Benzathine penicillin or (safe in preg)
Doxy (not safe in preg)

⇒ after 1yr we do CSF analysis if -ve it is latent syphlis. for latent TB we will give Benzathin penicillin 2.4 million units once weekly for 3 weeks

If +ve in CSF → then neuro syphlis

Dr. Naila Unbreen

Benzathine penicillin 2.4 million units every 4 hrly + probenacid for 10 day.
Then benzathin penicillin once weekly for 3 weeks

Hep B guidlines by Dr Ehtesham: Dr. Naila Unbreen

- Hep B is nucleic disease. It is very difficult to treat
- It is controlable not curable. Hep C is curable.
- Start antiviral when indicated. In hep C treat every pt. For Hep B life long antiviral therapy while in hep C, there is some duration.

Incubation period.

6 weeks to 6 months

features of acute hep B

fever, yellow discoloration of sclera, skin tender hepatomegally. elevated transaminases followed by recovery mostly. In <1% cases fulminant hepatitis

Will every pt of acute hep B is treated with AVT

No. just symptomatic treatment. cz 90-95% cases spontaneous full clearance of virus

- hospitalize pt if • altered sensorium, • prolong INR and treat nucleotide/nucleoside analogues (anti-viral agent) other wise no role to treat hep B.

Natural course of disease.

Full recovery in 90-95% spontaneously,
Chronic hepatitis in with horizontal transmission (tatoo's, unprotected intercourse, unscreened blood transfusion, needles) is 5-10%.
while in vertical transmission risk is 90%.
(from Hep B sAg +ve mother to child)

chances of HCC in Hep B is more than Hep C.
If vertical transmission or Ted Hep B virus DNA. then more chances
So USG + afetoproteins for surveilance

Dr. Naila Unbreen

What are sphases of ch. hep B.

1) Immune tolerant phase.
   hep B surface antigen +ve
   hepB eAg +ve
   PCR high +ve
   ALT Normal liver histology Normal.
=> e antigen +ve chronic HBV infection (New terminology

2) Immune active phase:
   ALT ↑ AbNormal liver histology.
   Hep BsAg +ve
   eAg +ve
HBV DNA PCR high (viral load).
=> e antigen +ve chronic hepatitis B.

3) Immune Control phase:-
=> e antigen -ve Inactive carrier phase.
   e-Ag -ve eAb +ve.
• sAg +ve. eAg -ve. HBV DNA low <2000 IU/mL.
   ALT normal Liver histology no liver dx.
=> e- antigen -ve chronic HBV Infection.

4) Immune reactivation phase.
   Both virus & immune sys. active
   core antigen +ve
   sAg +ve eAg -ve HBV DNA > 2000
   ALT ↑ liver histology abnormal.
=> e antigen -ve chr. hepatitis B.

5) Recovery phase.
   sAb +ve cAb IgG +ve. HBV undetectable
   rest normal.
   liver histology may be normal or abnormal.

CamScanner

Dr. Naila Unbeen

HBsAg -ve phase. or Accult HBV infection:- (tripple C DNA is still positive and hidden. If any immunosupresant given it will reactivated. so it is called accult HBV Inf). This is hindrance in treatment

⇒ Antigen of Hep B.

- Surface Antigen: HBsAg:- Infection.
  If persist >6mnth → ch. Infection.
- E antigen HBeAg:- Replication & Infectivity
- HBV DNA: by PCR.
- HBc Ag:-

⇒ Antibodies

1) Anti Hep B sAb:- Immunized.
d/t vaccination or (HBsAb +ve) or previous Infection:- HBcAb IgG +ve HbsAb +ve

2) HBeAb :- carrier state

3) core Ab:- Exposure. HBc IgM. (+ve in window period) 1st antibodies to appear.

HBcAb IgG:- sAg +ve → HBcAb IgG+ → Ongoing
sAg -ve → HBcAb IgG b → previous inf

Hep B vaccination:-

- Angirex B. 0, 1, 6 mnths
- AmBx - B
  <16yr. 0.5ml deltoid
  >16yr 1ml 1/M deltoid

In hemodialysis 2ml 1/M Deltoid 0, 1, 6 mnths
New regimen (accelerated):- heplisav B (2 doses) 0.5ml of heplisav at 0, 1 mnth

Dr. Naila Unbreen

Different serological patterns:

Hep B s Ag	Anti HBs	Anti HBc	Hbe Ag	Anti HBe	
+	−	IgM	+	−	Acute Hep B
+	−	IgG	+	−	ch hep with active viral replication
+	−	IgG	−	+	Inactive carrier stat. HepeAg-ve CHB with active viral repli.
−?	+	IgG	+/−	+/−	ch hep B with hetero typic anti HBs
−	−	IgM	+/−	+/−	Acute hep B.
−	+	IgG	−	+/−	Recovery from Hep B
−	+	IgG	−	−	Vaccination
−	−	IgG	−	−	False +ve / Inf in remote past.

CBC.

Treatment: • HBs Ag.

• PCR Hep B. DNA (Quantitative).

• LFTs. ALT, AST, GGT, S/Albumin/globulin AIP, bilirubin, PT

• HBe Ag.

• USG abd.

• Liver histology

Non Invasive:- fibroscan + elastography.

Invasive: biopsy.

• Vim silver man needle

• Menghini needle

• Trucut biopsy needle.

Investigations for comorb:

anti hep A antibodies

If -ve then go for hep A vaccine.

- Anti HCV , Anti HBV Anti HIV.
- other causes of ch. liver disease if indicated.

When to treatment ch. hep B:.

HbsAg +ve Offer { eAg. ALT. + PCR

↓

HbeAg +ve

HBV DNA > 20,000	HBV DNA > 20,000	HBV DNA > 20,000
↓	↓	↓
ALT ≤ ULN.	ALT > ULN but < 2×ULN.	ALT ≥ 2×ULN
(Don't treat)	(Don't treat)	(treat).
↓	↓	
Monitoring.	Exclude other causes.	
ALT + HBV DNA → 3-6m	① fibro scan ≥ F2 → then treat.	
HbeAg → 6 month	② if all other causes of ↑ALT R/o. and it persist and age >40 → treat.	

HbsAg +ve

↓

HbeAg -ve

HBV DNA > 2000	HBV DNA > 2000	HBV DNA > 2000
ALT ≤ ULN.	ALT > ULN but < 2×ULN.	ALT ≥ 2×ULN.
(Don't treat)	(Donot treat)	(treat)
↓	↓	
Monitor	Exclude other causes.	
ALT + HBV DNA - 3m.	① Fibroscan ≥ F2 → treat	
HBeAg Annually.	② if all causes of ↑ALT R/o. ALT persist, HBV DNA > 2000 age > 40 → treat	

Drugs to treat hep B virus

① Oral ② Injectables.

Nucleotide	Nucleoside analogue
Tenofovir alafenamide (TAF)	Lamivudin
Tenofovir disoproxil fumarate (TDF)	Telbivudin
Adefovir.	Entecavir 0.5mg.

✓ pegleated Interferons. α 2a. 180ug s/c once weekly for 48weeks.
α 2b

Liver transplant.

Benefits of oral:

Less adverse effects than interferons
Oral route
Greater HBV DNA supression & less expensive
save in advanced disease.

Adverse effects of oral

Infinite duration of Tx
Risk of resistance
less HBsAg (surface antigen) sero conversion (surface antigen is lost and surface antibodies are formed)

Benefits of interferon α2a.

Finite duration of treatment → 48weeks
No antiviral resistance, sustained response (if HBV DNA is < 2000 for more than 12 months after treatment end, it is sustained response).
It is better surface antigen seroconversion.

Adverse effect of interferon.

1) They hv lot of side effect.

less HBV DNA suppression
Expensive
Not save in advanced dx. rather contraindicated in cirhosis

Dose and Duration.

1) Normal liver :- Oral or Inj.
   Entecavir 0.5mg OD life long. or (Monotherapy)
   TDF 300mg OD " or
   TAF 25mg OD life long or
   Pegelated interferons 180ug s/c once weekly -> 48w
2) Fibrotic liver. same treatment as for Normal liver.
3) Compensated cirhosis :. peg interferon contraindica-ted. oral medications same.
4) Decompensated cirhosis :. peg Interferon contraindica-ted.
   and TAF is not given but any 1 of 2.
   Entecavir ~~0.5~~ 1mg OD for life long (Dose ↑)
   TDF 300mg life long

[TDF]
- relative older formulation
- decompensated cirhosis
- can given in pregnancy
- In HIV coinfection.
  300mg OD

[TAF]
- Newer formulation
- can given in derange EFR's
- Can given >60yr
- in Bone disease
- previous exposure to nucleoside analogue.
- In HIV co-infection
  25mg OD.

[Entecavir] 0.5mg OD
- In renal insufficiency but with reduced dose
- bone disease
  >60yrs of age
- Decompensated cirhosis

Dr. Nala Unbreen

Lamivudin 300mg · PO OD.
HIV co infection with TAF or TDF

Combination Therapy: for Hep B is generally not recommended
If pt. is treatment adherent, and compliant but there is incomplete reduction in HBV, then you can switch to another drug or combine two drugs (only exception)
Can we combine nucleositide & interferon a.
No.

Hep B + pregnancy

- Screening by HBsAg in 1st trimester
- If +ve PCR HBV DNA
  If > 200000 or advance fibrosis. or previous baby with HBsAg or HBsAg > $4 \log^{10}$ IU/ml
  If HBV DNA > 2lac :-
advanced fibrosis. TDf.
If previous baby & HBV :- start treat with TDF.
If HBsAg > $4 \log^{10}$ IU/ml :- start with TDF.

Start at 24-28 weeks (at beginning of 3rd Tri) and continue 12 weeks after delivery -
Mode of delivery: Not affected. NVD.
C-section can also offered
Breast feeding: Breast feeding allowed if HBsAg +ve and untreated or HBsAg + and TDF → allowed
Husband :- Offer screening to husband
If -ve → Give vaccination

If +ve → treat if indicated. Screening (HBsAg Anti HBcAb, IgG, IgM).

what to do with baby:

Start hep B treatment with in 12hrs after birth. Immunoglobulins + Vaccine (both)

Angirex 0.5ml Ant aspect of thigh. IM 0,1,6. CZ

postpartum monitoring of mother. 1, 3, 6 mnths of risk of flare

Needle prick injury:

HIV	0.3% risk
HCV	3% risk.
HBV.	30% risk.

Ask pt about vaccination status

HBsAg.

Do HBsAb levels. If >100 Do nothing

10-100 booster

<10 Immunoglobulins + Vaccine 0.06 ml/kg Angirex 1cc deltoid 0,1,6.

HIV + HBV co-Infection

start antiviral therapy for HIV + regardless of CD4 count

tenofovir based antiretroviral therapy.

TDF + Emtricitabin or

TDF + Lamivudin (available in Pak 300/300)

TAF + Emtricitabin or

TAF + Lamivudine.

Acriptega 50/300/300 (Dolutegvir/Lamivudin/TDF)

HCV + HBV co-infection:

HCV therapy alone causes reactivation of Hep B virus so treat HBV & HCV acc to respective guidlines

Dr. Naila Unbreen

If a person is

① HBsAg+ HCV+ start Direct acting antivirals for hep C and nucleotide analogues for HBV. as prophylaxis. Continue hep B prophylaxis 3 months more than hep C tx.

② HBsAg- HBcAb +ve and person is taking direct acting antivirals for hep C, Guidlines say monitor his ALT → whenever ALT rises → test for HBV reactivation.

Hep BV + HDV:

peg interferon α for atleast 48weeks is 1st line treatment of choice)

Oral antiviral with nucleotide especially if there is ongoing DNA replication.

Extrahepatic Menifestation

- PAN
- Glomerulonephritis (MPGN)
- Arthritis
- Dermatitis
- Polymyalgia rheumatica

All pts with replicative HBV inf and extra hepatic menifestation → start treatment with nucleastide analogue. Avoid interferone α in extrahepatic menifestation.

Hep B and renal insufficiency:

if eGFR < 60 start TAF

if on hemodialysis start TAF.

Dr. Naila Unbreen

HBV & Decompensated Liver Cirhosis

Pegalated interferon contraindicated
Start treatment with nucleotide analogue ↑ & immediately consider liver transplantation
and also monitor for side effects → lactic acidosis + renal function

when to stop or duration of tx of HBV

If peg interferons → defined therapy duration 48 weeks.

end pt. of tx depends upon 2 things if on nucleos(t)ide analogues
① liver status
② eAg status.

1 **Normal liver:** If eAg+ → stop tx once he acheived
i) stable eAg+ seroconversion
ii) Undetectable HBV DNA by PCR.
iii) Complete 12 mnths of consolidation therapy.
(after eAg is cleared and HBV ~~DNA~~ DNA undetectable 12 mnths of therapy after that).

If eAg -ve → Once pt achieves long term (3 or more yrs) ~~of~~ virological supression of HBV DNA, we will stop treatment. (simply continue treatment after undetectable DNA for 3yr) → follow up yearly.

If HbsAg+ with loss of HbsAg → Conti consolidation therapy for 6mnths to 1yr then we will stop.

2 **Fibrotic liver:**
life long tx mandatory.

(3) **Cirhotic liver**

life long treatment mandatory

Choice of Different Antivirals-

⇒ If Renal compromise:-
TAF or Entecavir
and entecavir is given with dose modification

⇒ If Decompensated cirhosis
TDF or Entecavir

⇒ If pregnancy.
TDF

⇒ If child bearing age & planing for preg.
TDF (AASLD guidline)
delay treatment if no advanced ~~cirhosis~~ fibrosis until child is born (EASL guidlines)

⇒ If women of child bearing age wants to become PCR -ve prior to preg.
TDF or peg interferon.

⇒ previous exposure to nucleoside analogue or resistance to lamivudine
TAF

⇒ Bone disease
TAF or Entecavir

⇒ Old pt. >60yr.
TAF or Entecavir

Monitoring of antiviral tx

~~Inf~~ Inv. for antiviral therapy efficacy
Inv. for antiviral safty
Inv. for liver dx stat.

Dr. Naila Unbreen

Inv. for antiviral efficacy:
LFT's
HBV DNA by PCR.
HBeAg every 3-4 months during 1st yr
then 6 to 12 monthly
HBsAg every 12 monthly. (esp if persistently undetectable HBV DNA)
If HBsAg undetectable then check HBsAb.

Inv. for antiviral safety
S/creat
e GFR.
S/PO4. every 3 monthly for first yr.
then 6 monthly
esp if pt is using TDF.

Investigation for liver
APRI score
FIB-4
Fibroscan } for liver cirhosis.
USG & a feto protein for HCC surveilance.

Antiviral Response

1) Virological
2) Serological
3) Biochemical
4) Histological response

① Virological response.

If some one is on treatment, or off treatment
On treatment virological response with nucleostide ana
⇒ HBV DNA < 10 IU/ml is → response
⇒ # less than 1log reduction in HBV DNA

after 3 months of tx → primary non response
⇒ HBV DNA is reduced by more than 1 log & is compliant to medicine, but still detectable after 1yr (12 months) of tx. → Partial response.
⇒ HBV DNA is red by >1 log after treatment.
→ break through

If treatment with peg interferon:
HBV DNA < 2000 IU/ml → Response

Off treatment
Sustained response: HBV DNA < 2,000 for more than 12 months after end of tx

(2) **Serological response**
eAg loss and development HBeAb.
sAg loss and development of HBsAb.

(3) **Biochemical response**
ALT normalization is confirmed every 3monthly for 1yr post treatment.

(4) **Histological response**
can be assessed by comparing pretreatment and post tx histology fi
If ↓ in necroinflammatory activity without worsening of fibrosis it is histological response.

Liver transplantation is acceptable option in HBV. but post transplantation prophylaxis is imp to prevent re infection of transplanted liver
HB immunoglobulin + Nucleostide antiviral

agents for prophylaxis. ↓ ↓ ↓ The re infection rate to <10%. ↑ 5yr survival to 80%.

End pt. acc. to guidlines

Main end point:
Supression of HBV DNA

Valuable end pt.
eAg+ → loss of eAg is valuable end pt

Additional end pt:
ALT normalization.

Optimal end pt.
loss of HBsAg.

With current therapy we will reach to functional cure of ch. hep. B. eAg -ve eAb +ve HBV DNA -. HbsAg -ve HbsAb +ve but CCC-DNA remains +ve. Upcoming antiviral therapies, they want complete cure of Hep C. including CCC DNA -ve that is complete cure of Hep B. But till date its functional cure only.

① HBV DNA > 20,000
DNA
ALT > 2× ULN
Liver Normal → Treat.

② HBV DNA > 2000
ALT > ULN
Liver fibrolic
HBeAg + or -ve → treat

Dr. Naila Unbreen

(3) Cirhotic liver any HBV DNA level → treat regardless ALT

(4) HBV > 20,000 and liver Normal and HbeAg ALT < ULN start treatment only if age > 30 yr. family h/o HCC, cirhosis or extrahepatic menifestations

(5) HBV > 2000 liver fibrotic ALT < ULN treat only if age is > 30 yr. or F/H of HCC or cirhosis or extra hepatic menifestation

(6) HBV ALT ≥ 2x ULN, HBV < 2000, normal liver → Quantification of HBsAg → if < 1000 don't treat if > 1000 treat

(7) ALT > ULN, fibrotic liver, HBV DNA < 2000 Quantification of HbsAg. if < 1000 Don't tx. if > 1000 treat.

D. Naila

Hepatitis C guidlines by Dr. Ehtesham. Lubreen

Hep C is an RNA virus B was DNA Virus.

Genolypes of HCV

6 major genolypes

genolype 1, 2, 3, 4, 5, 6 and genolyp Ia, Ib

most common in Pak, 3.

⇒ Treat all pts of hep C regardless of viral load

Extrahepatic syndromes of Hep C virus.

Cryogldbulenemia

Liclen plamus

porphyria cutanea tardia

Monoclonal gammopathy of ~~mono~~ undetermined significance ~~origin~~

Non hodgkin lymphoma

3 patterns of Kidney Injury

1) Secondary membrano proliferative glomerulonephritis

2) Cryoglobulinemic glomerulonephropathy.

3) Membranous nephropathy

Treatment Navie:-

All those pts who has never been treated for HCV

Treatment experienced.

which were previously treated with ① peglated interferones and ribavarin, ② sofosbuvir and peglated interferons and ribavarin or ③ sofos + ribavirin are called treatment experienced.

Investigations: pre assessment

If CBC: if <10 we will reduce ribavarin

LFTs albumin PT INR

RFTs eGFR.

RBS. (Direct acting antivirals leads to some hypoglycemia

Anti HCV by ELIZA.

HCV RNA PCR. Qualitative + Quantitative

HCV core antigen by ELIZA (if PCR not available)

USG abdomen: Cirhosis + portal htn.

(core antigen is a marker of viral replication)

Fibroscan transient elastogeaphy: Liver stiffness

< 7.5 kPas = No fibrosis

7.5 - 12.5 = fibrosis

> 12.5 kPas = cirhosis

Investigation for comorbid, co inf

Hep BsAg → if -ve → start vaccination.

HepA antibody → -ve → start HAV vaccination

* → preg test if needed

liver biopsy → fibrosis / cirhosis / potential etiology.

* anti HIV.

=> Anti HCV antibodies (if +ve) by ELIZA. →

Do HCV RNA Quantitative PCR.

to see whether pt is spontaneously recovered.

If PCR is neg → pt is spontaneously recovered

If PCR is +ve → pt is viremic → needs tx

If PCR not available → Do HCV core antigen by Eliza

=> HCV PCR quantitative PCR and genotyping is not required

Cz we have pangenotypic regimen and for

Dr. Naila Unbreen

HCV treatment usually viral load is not imp to see liver status

Liver status assessment

1) clinical features of cirhosis → either he is having bleeding vauces, ascites, encephlopathy.

2) USG abd. to look for portal htn → small shrunken liver, spleenomegally, dilated portal vein, ascites

3) Non invasive test for staging liver fibrosis

Fo	F_1, F_2, F_3	F4
No fibrosis	fibrosis	cirhosis

this is done by APRI score
Fib 4 score age AST, ALT,
fibroscan elastogsaphy

⇒ Three posibilities

1) **Normal Liver.**
- no clinical feature
- USG normal.
- APRI < 0.5
- FIB 4 < 1.5
- fibro scan < 7.5 Fo.

2) **Fibrosed liver**
- No clinical features
- USG abd. normal
- APRI 0.5 – 1.5
- FIB 4 1.5 – 3.5
- fibro scan 7.5 – 12.5 Kpas (F_1, F_2, F_3)

3. Liver Cirhosis
- clinical features +v bleeding vauces, ascites enephlopathy
- USG show signs of portal htn
- APRI >1.5

CamScanner

FIB 4 : >3.5

Fibroscan F4 >12.5 KPas

Indications of hep C treatment

1) Everyone with +ve HCV PCR must be treated regardless he is tx naive, treatment experienced he has recently acquired HCV or having ch. HCV inf but few exceptions.

- Antiviral therapy not tolerated.
- If Directly acting antivirals for HCV is contra indicated i.e if he is taking phenytoin or carba mazepin or phenobarbital, they are P450 inducers and they ↓es concentration of antivirals → either change antileptic or concomitent use of these 2 are contraindicated.

HCV Protease inhibitors like glecaprevir, pibrentesvir are contraindicated in decompesated cirhosis (CP B,C) or there is h/o decompensation in past, dont give him.

Poor life expectencies d/t some non liver dx like pt. with cancer, heart failure. HCV tx is contra indicated.

2) If someone has significant fibrosis (F_2, F_3 we will do urgent HCV treatment

3) Cirhosis (F_4) compensated cirhosis or decompensated cirhosis → treat it

4) Extra hepatic menifestations

5) HCV recurrence after transplantation

6) Rapid evalution of liver disease risk i.e

If somebody is having comorbidities, then can lead to rapid evolution i-e HBV, HCV coinf, HCV, HIV coinf or smbody going to hv stem cell transplant or solid organ transplant

7) Red risk of HepC transmission special population who can transfer virus to others female of child bearing age & want to pregnant hemodialysis or homosexual males

What are goals of HCV therapy:

1) To cure / eradicate HCV infection. by achieving
2) SVR. so our aim is to slow the ch. inflammatory process initiated by HCV inf bcz it causes hepatic necroinflammation. In non cirholics we want to end fibrosis and minimize risk of cirhosis. In cirholics we want to slow down worsening of cirhosis to decompensation. and risk of HCC, and all cause mortality as well as liver related mortality
2) To prevent and treat extrahepatic menifestations of HCV
3) We want to improve quality of life & remove stigma
4) we want to prevent further HCV transmission

⇒ DAA's (Direct acting antivirals)

3 main gps.

1) Nonstructual NS 3 4a protease inhibitors
They end with "previr"
- ✓ Voxalaprevir — Simeprevir
- ✓ Glecaprevir — Grazoprevir

2) NS 5a Inhibitor 'asvir'
3) Ns 5b inbibitor

Ns 5a Inhibitor.
Declatasvir
Velpatasvir
Pibrentasvir

NS 5b inhibitors 'uvir'
Sofosbuvir Nucleoside Inhibitor
Dasabuvir Non nucleoside inhibitor

Treatment may be genotyp specific or pangenotypic. pangenotypic is recommended now.

1) Velpaget/ Hilvel → Sofos + velpatasvir 400/100.
OD for 12 weeks.

2) Sofos + Declatasvir 400 + 60mg.
single single drug

3) Sofos + velpatasvir + vaxilaprevir 400/100/100
voseni → OD for 12week.
available in Pak and 1course costs abt 2-3lac.

4) Glecaprevir + pibrentasvir 100/40mg.
3tablets once daily → duration depends upon liver status
Maveret. (not available in Pak)

Genotypic specific.
ie Sofos + ladipesvir etc
400/90 1×OD

Treatment. Dr. Naila Unbreen

classify in 4 gp acc. to liver status and treatment naive/experi.
Normal liver, fibrosed liver or compensated liver (CP A)

1) Normal liver + treatment Naive
2) Normal liver + treatment experienced
3) Compensated cirhosis + treat Naive
4) Compensated cirhosis + treatment experience

1) Normal liver + treatment naive

If clinical features normal USG normal, APRI, FIB 4 and fibroscan shows normal liver + HCV + but didn't took any treatment

There are 3 treatment options

1) Sofos + Dacla 400+60 for 12 week.
2) Sofos + velpa 400/100 for 12 week.
3) Gleca + pibrentasvir for 8 week (not available in pak.).

2) Normal liver + Treatment experienced.

1) Sofos + Dacla + Ribavarin 12 weeks
2) Sofos + velpa with/without ribavarin 12 weeks
wt base Ribavarin dose
If <75kg 1000mg
>75kg 1200mg.
3) Glecaprevir + pibrentasvir for 12 weeks

3) Compensated cirhosis + Treat Naive

4 options

1) Sofos + Dacla + Ribavarin 24 weeks
2) Sofos + Velpa + Ribavarin 12 weeks
3) Sofos + velpa + Vaxillaprevir 12 weeks
4) Gleca + Pibrentasvir 12 weeks

4) Compensated cirhosis & treatment experienced
we donot offer sofos + dacla + ribavarin cz either they dont response or if they response they ll relapse
1) Sofos, + velpa + ribavarin 12weeks acc. to guidlines but can extend to 24weeks
if ribavarin is intolerant then
Sofos + velpa → 24weeks
2) Sofos + velpa + vaxilla 12weeks
3) Gleca + pibrent 16weeks
This is very difficult to treat.

Trick

Treat all pts with Sofos+velpa± Ribavarin.
1st catagory sofos velpa and remaining 3gps sofos velp + ribavarin
⇒ If non responder or relapsee
go for sofos velpa vaxila for 12weeks.

End pt of Hep C treatment.
At 12weeks after end of tx → SVR 12
24week after end of tx → SVR 24
⇒ we have 3 options at end of Hep C tx
1) Undetectable HCV RNA PCR Quantitative (done with assay* with detection* (of lower limit) < 15 IU/ml
2) HCV core antigen → undetectable HCV core antigen by Eliza
3) Undetectable HCV PCR Qualitative (done with an assay with lower limit of detection (< 1000 IU/ml

Re infection:- HCV is treated + SVR achieved ⇒ he again acquired HCV inf
If person is non responder or relapser go for velpa, sofos + vaxilla for 12weeks
or sofos + gleca + pibren 12weeks

Recently acquired HCV (don't use acute HCV term)
presence of anti HCV antibodies or HCV RNA not detectable in recent 12mnths.
most of time previous test not done/available.
so previous presence of HCV RNA with or without anti HCV antibodies with 3 fold ↑ in ALT from base line + high risk behavior in last 6 months (IV drug abuse/unprotected sexual/blood transfusions)
+ absence of other causes of acute liver injury
→ we can label recently acquired HCV inf.
Tx:- Velpaget 400/100mg OD 12weeks.
gleca + pibrent → not available in Pak
check SVR at 12weeks & 24weeks after end of treatment
No indication of antiviral therapy as post-expo-sure prophylaxis in absence of documented HCV tramission → 1st document HCV transmission → then treat (even in needle prick injury)
(In HIV & HBV it is present)
Counselling
proper adherence to drugs,
No abstinence but avoid alcohol.

prevention of conception until treatment is done
prevention of reinfection
Hep A & B vaccination

Monitoring during treatment.

No lab monitoring required
but if pt is taking antidiabetic medications monitor for hypoglycemia
if on warfarin → monitor with PT/INR.
subtherapeutic anticoagulation
if someone with decompensated cirhosis (CP B) monitor Hb levels who are not on ribavarin
if Hb < 10 ↓ ribavarin dose by 200mg
Hb. < 8.5 g/dl stop ribavarin

ALT > 10 x ULN stop antiviral
HCV RNA PCR or core antigen by Eliza at 12 week (SVR-12) or 24 weeks (SVR 24) after the end of tx to see whether treatment is successful or pt. is non responder.
if reduced eGFR monthly monitoring of RFTs

Post treatment monitoring/followup

Depends upon outcome. whether the pt. is cured (achieved SVR) or not cured) + stage of fibrosis fo, f1 stage or f2, f3, f4

1) cured + fo, f1 stage:
- low risk: achieved SVR 12 or 24 → no further followup required

Dr. Naila Unbreen

HCV Inf. with decompensated cirhosis c.B/c

3 possibilities

(1) If MELD <18-20 + decompensated cirhosis + without HCC → first tx Hep C then go for liver transplant
Sofos + velpa + Ribavarin for 12weeks

2) Start ribavarin at low dose 600mg OD. If tolera-ted ↑dose slowly depending upon pts tolerance and Hb levels.

If ribavarin is contraindicated or not tolerated we can give sofos, velpa for 24weeks

(2) If MELD ≥ 18-20 + decompensated cirhosis e no HCC → first do liver transplant then treat hepatitis C. with sofos + velpa + ribavarin 12weeks

(3) If MELD ≥ 18-20 + decompensated cirhosis e no HCC but waiting time in transplant list is more than 3-6 months → 1st tx hep C then go for liver transplant
Sofos velpa & ribavarin 12weeks

Pregnancy & hep C.

⇒ We will not treat hepC in preg. wait and treatment started after delivery.
⇒ Mode of delivery → NVD. C section not compulsary.
⇒ Breast feeding allowed unless nipple cracks and bleeding (allowed in hbv hcv but not in HIV)
⇒ Follow up of mother after delivery.
HCV RNA PCR 1yr after delivery → 10% cases spontaneously recover

how to treat / follow up baby.
Do anti HCV antibodies by Eliza at age of 18 months of age (1½ yr).
If -ve → dont worry.
if +ve → do HCV RNA PCR at 3yrs of age.
If PCR is +ve → then treat HCV at 12yrs of age or when weight is ≥35kg. with direct acting antiviral.

how to treat HCV in children + adolescence.
12-17yrs.
Sofos + ledipesvir 400/90 1×OD 8-12weeks.
(for genotyp 1,4,5,6 it is considered superior)
for genotype 2,3 velpaget 400/100 1×OD 12weeks

HCV and immune complex menifestations of HCV.
We treat HCV
i.e if mixed cryoglobulenimia or renal menifestations treat HCV with pangenotypical regimen
velpa 400/100 1×OD 12weeks.
HCV associated lymphoma → treat with direct acting antivirals + chemo for lymphoma but careful for interactions
⇒ If you have to give rituximab with HCV ass renal dx. Discuss with multidisciplinary team.
⇒ HCV & renal dysfunctions:
3 possibilities
① e.GFR ≥30 Mild to moderate renal impairment 1× would be same → pangenotypic antivirals

velpaget 400/100 1xOD 12weeks

2) if eGFR < 30
severe renal impairment
Sofos with caution as it is nephrotoxic
if no other option as in Pak no other tx available
give sofos + velpa but with caution
try to give sofos free regimen. i.e mavyret.

(3) End stage renal disease with hemodialysis
pangenotypical regimen.
best is glecaprevir + pibrentasvir → mavyret
but since it is not available we can also get velpaget.

Decompensated cirhosis + renal impairment
2 possibilities.
1) eGF ≥ 30 with decompensated cirhosis
velpaget + ribavirin for 12 weeks. <75 = 1000kg mg
>75 = 1200kg mg

2) Decompensated cirhosis + eGFR < 30
Sofos + velpa 24week
without ribavirin.

HBV + HCV co infection.
whenever HBV & HCV coinf always test for HIV
no change in HCV infection
velpaget 400/100 1x OD for 12week
HepC tx alone causes reactivation of hepB virus

so treat HBV & HCV and start nucleos(t)ide analogue. HBV tx would be continued for 3 months after completion of HCV tx. ends.
If HbsAg +ve → co treat HBV & HCV.
If HbsAg -ve and Anti Hep B core antibodies +ve → and pt is taking DAA for HCV → we will do monthly ALT → cz there is risk of reactivation of HBV.

Treatment of ch. HepC in HCC pt.

If pt. is having fibrosis of compensated cirhosis with HCC → and is eligible for resection or ablation therapy → for HCC first treat HCC tx & then give treatment for HCV.
If HCC pt. he is awaiting for transplantation & is long awaiting time → then 1st treat hepC then go for liver transplant.

Ch. HCV whose HCC has been treated

after complete response to HCC therapy treat HCV with velpaget. once SVR achieved then do life long surveilance of HCC. by 6 monthly USG

Retreatment of DAA's failure

HCV resistence testing (try to offer) if possible.
Non responder :- HCV course completed but SVR not achieved. or HCV treatment started, after 1 mnth he left the treatment and in followup HCV +ve
relapser :- SVR achieved but again becomes HCV+

high risk : obese, DM type II, alcohol
need follow up

2) cured + fibrotic (f_2, f_3) or cirhotic liver / 4
if achieved SVR but fibrosed or cirhosed liver, life long follow up.
i) Surveilance of HCC
ii) surveilance for esophageal varices.
iii) Surveilance for HCV reinfection

i) 6 monthly USG and a-feto protein ↓ risk of HCC is reduced after SVR but not abolished.
ii) • If varices present prior to Tx → do 6-12m endo-scopy
• If varies not present → platelet count + fibroscan elastography annually.
if platelets fall below 1,50,000 and fibro scan show ↑ in 20kpas → again do 6-12mnthly endoscopy.
iii) encourage behavior modification to prevent HCV reinfection.
do HCV RNA for reinfection - 6 monthly or once a year → if +ve restart tx. with out delay.

3) SVR not achieved but normal liver f_0, f_1
we do fibroscan to monitor progression of fibrosis (we can do APRI score, FIB 4.)

4) SVR not achieved but liver in not normal (fibrotic or cirhotic)
2 things

Dr. Naila Unbreen

Life long followup for HCC
Life long followup for esophageal varices.

CamScanner

GPE Examination Check List

Pre-Exam
Stand on right side of patient
Greetings: Asalam-o-Alaikum
Introduction
Consent
Ask examiner you will like to expose patient fully , have drape , screen for privacy
Ask Patient Name and call him/her by name instead of calling Aman g , Bibi etc. Meanwhile assess Hoarsness
Look and Ask if patient is having an IV line (Branula) , if yes , at which site
Exposure : remove shirt (If time allows)
Position: lying straight on bed with small pillow under head , arms by the side OR sitting
Look for NG , Foley , Drain and its contents
General Look Go to foot end
Age , gender , posture , comfort , demeanor , built/physique
Look for catheters , sputum jar , urine colour
Ask for tenderness in any part of body
Vitals
Insert Thermometer in axilla and check temperature at end
Pulse : rate , rhythm , volume , character , check for collapsing pulse
Blood pressure
Respiratory rate
Hands
Nails : Clubbing (in profile view) , Leuconychia , Koilonychia , splinter hemorrhages , Cyanosis , Quincke's sign , Discolouration (Mee's line , Beau's line) , Nail pitting ,
Fingers : PIP/DIP nodules , Joint swelling , subcutaneous nodules ,
Hands : feel palm for temperature and sweating , deviation , palmar erythema , wasting of palm or guttering at dorsum , Pallor , cyanosis **Skin:** is skin tight?
Arm : look for bruises , Tatoos Epitrochlear Lymph nodes
Axilla : axillary lymph nodes , Acanthosis nigricans
Face
Scalp: deformity , hair
Face: complexion , 7th nerve , puffiness , shape , mask like , malar flush , butterfly rash , coarse skin
Eyes: Ptosis , miosis , pallor , jaundice , Arcus , calcification , dryness , Thyroid signs (staring look , exophthalmos , lid lag, lid retraction , loss of lateral 1/3 of eyebrows in hypothyroidism)
Nose: Lupus pernio
Lips: cyanosis , angular stomatitis ,
Oral Cavity: oral ulcers , on palate , blackish discoloration in mucormycosis , uvula , Ah test, Orodental Hygiene
Tongue: glossitis , cyanosis , pallor on ventral surface , Color (red beefy , strawberry) , aphthous ulcers , Deviation of tongue , macroglossia
Jaw : ask him to clench teeth (check proganthism)
Neck

Mees Line

Beau's Line

fig. 152-9 Fig. 152-10 Fig. 152-11

Neck : ask him to take sip of water (thyroid) , JVP , neck veins
Cervical lymph nodes : check from back …….. Look for spider angiomas , any finding , sacral edema
Exophthalmos , protrusion of eyes, spine tenderness
Chest : Visible deformity , Gynecomastia , listen to heart and back of chest if clubbing +ve. Auscultate heart if severe anemia (for murmur ,) , sternal tenderness
Abdomen : Visible deformity (check liver & spleen if lymphadenopathy or pallor) Abdominal lymph nodes
Inguinal region : hernia orifices , inguinal lymph nodes
Legs: skin lesions , pedal edema , visible deformity
Ophthalmoscopy :
Tell examiner you would like to examine genitalia
End of exam
Say thanks
Drape the patient

Minimum Exam in GPE

04 Vitals (Pulse,BP,RR,Temp)
06 Non Vitals :

i. Hands & Arms
ii. Face (Scalp,face,eyes,mouth)
iii. Thyroid
iv. JVP
v. Lymph Nodes
vi. Legs

Examination Sequence
sitting from front
sitting from back
lying at 45 degree
flat

Acromegaly Scheme

Command: GPE

Vitals		
	Pulse	
	B.P.	HTN in 15 % cases
	R.R.	
	Temp	
Hands		
Hand Shake	1. Moist, doughy hands with 2. Excessive sweating & 3. Enveloping handshake 4. Thick skin	
Morphology	1. Large hands 2. broad palms 3. spatulate fingers 4. volume of hands is increased	
Carpal Tunnel Syndrome	Wasting of the thenar eminence	
	Look carefully for scar of previous surgery (hidden by the crease of the wrist).	
	Check motor component of thumb: Weakness of flexion, abduction and opposition of thumb	
	Diminished sensation over lateral three and half fingers	
	tap over flexor retinaculum ; patient may experience tingling	**Tinel' Sign**
	Ask the patient to hyperextend the wrist maximally for 1 min; this may bring on symptoms i.e. dysaesthesia over the thumb and lateral two and half fingers):	**Phalen's test** / Reverse Prayer Sign
Arms & Axilla		
	skin tags	Molluscum Fibrosum
	Black velvety papillomas	Acanthosis Nigricans
Face		
Forehead	Prominent supraorbital ridges	
Nose	Large Nose	
Oral Cavity	Large lips	
	Protrusion of the lower jaw	prognathism

	ask the patient to clench his teeth and note	malocclusion and splaying of the teeth i.e. interdental separation
	Show your tongue : look for impressions of the teeth on the edges of the tongue	macroglossia
Eyes		
	Bitemporal Hemianopia	
	Fundoscopy , DM, HTN Retinopathy	Optic atrophy
Neck		
	Goitre	
Chest		
	Gynaecomastia	
	Galactorrhoea	
Abdomen		
	Hepatomegaly	
	Splenomegaly	
Musculoskeletal		
	Osteoarthrosis	
	Chondrocalcinosis	
	Kyphosis (forward bending) , Check proximal myopathy	
Precordium		
	Displaced apex beat , pitting edema for HF	cardiomegaly
Tell Examiner you would like to do		
	Examine urine for sugar	impaired glucose tolerance

Legs: pedal edema, thickened heel pad

Description

GPE of this cooperative gentleman revealed

- Pulse of 84.min, regular.
- His Brachial Blood Pressure is 140/80 mmHg
- Respiratory rate is 20/min
- Axillary Temperature is 99 °F

Handshake was Enveloping. Hands are large, Moist, doughy, with Excessive sweating. Palms are broad, with spatulate fingers. Volume of hands is increased with thick skin

Tinel' Sign: tap over flexor retinaculum

Command: **Examine the pulse and do the relevant examination**

Pre-Exam
Stand on right side of patient
Greetings: Asalam-o-Alaikum
Introduction
Consent
Ask Patient Name and call him/her by name instead of calling Aman g , Bibi etc.
Position: at 45°
Ask if patient is having an IV line (Branula) , if yes , at which site
Exposure : ideally remove shirt, if does not allow, INFORM examiner and expose from clavicles to umbilicus
Look for NG , Foley , Drain and its contents
Insert Thermometer in axilla and check temperature at end
EXAMINATION
Radial Pulse: rate , rhythm , volume , character , vessel wall Check for radio-radial delay Check for radio-femoral delay
Check **Brachial** pulses B/L
Check **Carotid** pulses one by one : comment on slow-rising , bisferiens , parvus
Check B/L femoral pulses
Check B/L popliteal pulses
Check B/L posterior tibial artery
Check B/L dorsalis pedis artery
Apply BP cuff on arm , pulsus alternans : deflate cuff slowly , no of sounds double when cuff is deflated little below systolic BP pulsus paradoxus : deflate cuff 2mmhg , sounds heard only in exp first … on further deflation , sounds heard in insp too Difference between these two pressures is pulsus paradoxus
Examine the precordium and relevant specially opthalmoscopy

Gastrointestinal System Examination Check List

Command: Examine the abdomen and do the relevant examination

Action	
Pre-Exam	
Check Environment comfortability : Light , temperature	
Stand on right side of patient	
Greetings: Asalam-o-Alaikum	
Introduction	
Consent	
Ask Patient Name and call him/her by name instead of calling Aman g , Bibi etc.	
Position: Supine, arm by the side of patient Head resting only on 1 or 2 pillows	
Ask if patient is having an IV line (Branula) , if yes , at which site	
Exposure : From nipples to mid-thigh If could not , tell examiner you will to expose to this extent	
Look for NG , Foley , Drain and its contents	
Insert Thermometer in axilla and check temperature at end	
Inspection	
From: Above, Foot end and from right side of patient Ask him to take deep breath Elevate your head سر اوپر اٹھائیں	Divarication of Recti
Shape of abdomen; If distended, generalized or localized	
Abdomen moving with respiration	
Pattern of respiration	
Umbilicus	
Any visible skin deformity	
Visible veins; If yes , direction of flow	
Visible pulsations	
Scar Marks , Ascitic tap marks , adhesive sticking applied	
Pattern of pubic hair distribution	
Check Hernia orifices , Cough Impulse, Ask patient to cough and see bulging at site of Hernial orifices	
Palpate inguinal Lymph Nodes	
Palpation	
Ask for tenderness	
Warm hands if needed	
During palpation , look at face of patient [for tenderness]	

Superficial palpation … in S shape ; LIF →Lt.Lumbar →LHC →Epigastric → Umbilical →Hypogastric → RIF → Rt. Lumbar →RHC Assess for mass , Muscle tone : soft , guarding If mass palpable , ask patient to LIFT neck [tenses abd. Muscles] ..abd. wall mass still palpable , intraabdominal NOT	
Palpate for Liver , **If palpable , percuss** upper border in breath held in expiration use dipping method if massive ascites Span in Cm	Span, Edge,Surface, Consistency
Palpate Spleen, **If not ,** roll towards yourself and then palpate **Still Not palpable, Percuss** over lateral chest (Traube,s Semilunar Space) for dullness over spleen If felt , ask him to take deep breath	Moves with respiration
Bimanual palpation for Kidneys	
Aortic Lymph Nodes	
Palpate for urinary bladder	
If visible pulsation , check is it expansile	
Percussion	
Percuss upper border of urinary bladder	
Shifting dullness	
Fluid Thrill	
Auscultation	
Bowel Sounds at umbilicus	
Hepatic Rub	
Splenic Rub	
Renal Bruit on both sides	

Examination of Genitelia:
Scrotal examination, testicular atrophy

Para

Tell examiner you will like to do Per Rectal Examination	
Relevant Exam	
Elevate head end to 45 ° and check for 1. JVP 2. Precordium (IE, CCF) 3. Sternal tenderness	
Ask him to sit and examine for:	
Dorsum of Hands: 1. Deformities of RA 2. Nails: I. Leukonychia II. Koilonychia III. Clubbing IV. Guttering	
3. Spread your hands ہاتھ پھیلا لیں /Flapping Tremors	Asterixis
4. Palms : ہاتھ سیدھے کر لیں i. Palmar Erythema ii. Anemia iii. Dupuytren contracture	

5. Pulse	
6. Bruises on arms, ,Tatoos	
7. Epitrochlear Lymph Nodes	
8. Axillary L.N,	
9. **spider angiomas above the level of nipple**	
10. Gynecomastia , Sternal Tenderness	
11. Loss of scalp hair	
12. Eyes: i. Pallor ii. jaundice ,	
13. Face: i. facial puffiness ii. parotid swelling	
14. Mouth: i. Tongue : glossititis ii. oral ulcer iii. angular stomatitis iv. Lichenoid Lesions v. Waldeyer's Ring	
JVP (if ascites is there)	
Legs: Pedal Edema, Pyoderma gangrenosum, Erythema Nodosum (Sarcoidosis)	
Go Behind the patient	
15. Cervical L.N. 16. Chest : Percuss and auscultate bases of lungs ; effusion , crepts (sarcoidosis)	
TELL EXAMINER YOU WILL LIKE TO DO	
Examination of genitelia : for testicular atrophy in CLD	
PR rectal examination	
Breast exam in suspecting metastatic Breast disease	
Slit Lamp exam (Wilson's) and Detailed chest exam (Alpha 1 antitrypsin deficiency)	

CVS System Examination Check List

Command: **Examine the precordium and do the relevant examination**

Pre-Exam
Stand on right side of patient
Greetings: Asalam-o-Alaikum
Introduction
Consent
Ask examiner you will like to expose patient fully , have drape , screen for privacy
Ask Patient Name and call him/her by name instead of calling Aman g , Bibi etc.
Position: at 45°
Ask if patient is having an IV line (Branula) , if yes , at which site
Exposure : ideally remove shirt, if does not allow, INFORM examiner and expose from clavicles to umbilicus
Look for NG , Foley , Drain and its contents
Insert Thermometer in axilla and check temperature at end
Inspection
From: foot end and from right side of patient
Shape of chest
Visible apex beat
Visible pulsations in chest , neck (dancing carotids) , suprasternal , epigastrium and RHC
Scars e.g. mid-line sternotomy scar
Visible veins ; If yes , direction of flow [to be assessed on palpation] for SVC obstruction
Neck veins : engorged
Palpation
Warm hands if needed
Tenderness : First ask then check by palpating
Apex Beat: on lying supine →moderate left lateral→ on sitting & leaning forward→check on right side for dextrocardia → impalpable Comment on Character , area
Place hand for thrill on left side vertically
Place hand for palpable P2 on pulmonary area horizontally
Place hand for palpable thrill on A2 horizontally
Palpate right side neck for radiation of AS
Check for left parasternal heave
Check epigastric heave
Palpate for pulsatile liver + check JVP and do hepatojugular reflux

Auscultation
Keep THUMB on carotid
Listen at **mitral area** for S1 and Gallop rhythm Listen at **pulmonary area** for S2 and splitting

At **Mitral area** Listen for MS , AS , Gallop Rhythm and any other murmur Hold breath in end inspiration (insp) and expiration(exp) and check effect on murmur Check for radiation in axilla Change to bell , auscultate . then ask to be left lateral (for MS) On return , switch back to diaphragm
At **Tricuspid Area:** Auscultate , then at end insp and exp
At **A2 Area:** Auscultate , then at end insp and exp
At **Pulmonary Area:** Auscultate , then at end insp and exp
At **A1 Area:** Auscultate , then at end insp and exp
Auscultate in neck for radiation and carotid bruit
Ask patient to sit and lean forward , Auscultate on A1 & A2 for AR
Relevant Examination
Auscultate base of lungs for crackles , ronchi (COPD →A.fib) , pleural effusion (CCF)
Check sacral edema
Nails : clubbing , cyanosis , splinter hemorrhages , Quincke's sign
Fingers : feel pulp for Osler nodes , gangrene , nicotine staining
Palm: janeway lesions , pallor ,
Pulse: rate , rhythm , volume , character , radio-radial and radio-femoral delay Check for collapsing/water-hammer pulse (ask for pain in shoulder first)
Check Blood Pressure
Look for needle marks (IV drug abuse) in both arms
Look for tendon xanthomas
Face: facial puffiness , malar flush , head-nodding (Demusset's sign)
Eyes: Pallor , jaundice (due to congested liver) , Xanthelasmas
Mouth : Central cyanosis , pulsating uvula (Mueller's sign in AR)
Neck: You have already checked JVP , just show to examiner as you are looking for JVP , Thyroid
Abdomen : ask tenderness , Palpate **liver** , if palpable , check upper border and span , Palpate **spleen** Shifting dullness , fluid thrill for ascites (CCF) Palpate kidney if HTN+ve for Polycystic kidney disease , Ausculate renal artery bruit
Auscultate Femoral Arteries : for Tranbe's pistol shots , Durozier's sign
Check Pedal oedema , Erythema marginatum
Feet : same as hand , gangrene
Ophthalmoscopy , if no time , inform examiner Comment on Roth spots , Diabetic and hypertensive changes
End of Exam
Cover/drape the patient
Say Thanks

Description of precordial Examination & Relevant

Opening Sentence	Precordial examination of this gentleman who was conscious, cooperative and comfortable during examination (/at rest) revealed
Inspection	1. visible pulsations in the precordium , neck & epigastric/RHC area. Without any 2. chest deformity (shape) or 3. scar marks (sternotomy, thoracotomy) 4. Neck veins are distended/engorged (JVP). 5. JVP is raised 5cm above the sternal angle with CV wave(TR) with +ve heapto jugular reflex
Palpation	1. Apex beat is well localized in the 5th intercostal space , just medial to MCL, its tapping in character. 2. There is left parasternal heave and 3. Pulmonic component of 2nd heart sound is palpable. 4. No thrill is palpable.
Auscultation	1. Both first and second heart sounds are audible 2. First Heart sound is loud at apical area 3. Pulmonic component of 2nd heart sound is loud with normal splitting. No 3rd or 4th Heart sound is audible. 4. There are no added heart sounds (OS, EC, Metallic sounds/click, Pericardial rub, pleuro-pericardial rub). 5. A Grade 3 low pitched, rumbling , mid-diastolic murmur is present at apical area , best heard with bell with breath held in expiration in left lateral positon. 6. A Grade 3 Pansystolic murmur is present at left lower sternal edge, best heard with diaphragm and breath held in inspiration. 7. Both the bases of lungs are clear
Pulse	Radial Pulse is 72/min, regular, without any special character. There is no radio-radial or radio-femoral delay.
B.P.	Brachial B.P. in right arm is 120/80 mmHg
Temp	Afebrile (Normal temp is 97.5 – 99.5 F: Hutchison)
JVP	Already told
Relevant Examination On Relevant Examination	
+ve findings	He has got pallor. Etc …. Then tell negative ones
Hands	There are <u>no peripheral stigmata of infective endocarditis</u> (clubbing, splinter hemorrhages, nail fold infarcts, osler nodes, janeway lesions) There is a tatoo mark/needle marks on right forearm. There is no pallor,jaundice, cyanosis, malar flush. Light reflex intact (Argyl Robertoson pupil in AR) Orodental hygiene is adequate. There is no heapto or splenomegaly. No evidence of free fluid in the abdominal cavity. No tenderness in flanks (renal involvement)

	No scar at antecubital fossa or femor (of cardiac catheterization) No sacral or pedal edema. No roth spots on fundoscopy Patient is able to move all four limbs with B/L down going plantars

Viva :

Based upon the findings , my diagnosis is

1. Mitral Stenosis with pliable and pulmonary hypertension,
2. Most likely due to Rheumatic Heart Disease,
3. Patient is not in Heart Failure at the moment
4. Without any evidence of thromboembolic phenomenon
5. And possible in the sinus rhythm

Valvular Heart Disease Severity Criteria & AHA 2014 Class 1 Indications of Intervention

Murmur	Echo Criteria of Severity	Class 1 Indications of intervention
Aortic Stenosis Vmax= max aortic velocity	i. Aortic valve area ≤1.0 cm^2 + ii. Resting Aortic Vmax < 4m/s OR iii. Mean Pressure Gradient <40 mmHg	**1. ALL SYMPTOMATIC patients** On history or on exercise testing (Stage D1) **2. ASYMPTOMATIC** patients with severe AS + **LV Dysfunction** LVEF <50%(C2) **3. severe AS** (stage C or D) when **undergoing other cardiac surgery** **Indications for TAVR in AS** 1. Indication for AVR BUT **Prohibitive** surgical risk (predicted risk with surgery or major comorbidity>50% at 1 year or or >3 organ systems compromised) 2. Indication for AVR BUT **High** surgical risk(STS predicted risk of mortality>8% or ≥2 organ systems)
Aortic Regurgitation ERO= Effective regurgitant orifice Vena Contracta	i. Regurgitant volume > 60ml/beat, ii. Regurgitant fraction >50% iii. ERO ≥ 0.3 cm^2 iv. Vena Contracta > 0.6 cm v. Doppler jet width >65% of LVOT	1. All **symptomatic** patients (D) 2. **Asymptomatic Severe** AR with **LVEF <50%** (C2) 3. **Severe AR** (C or D) while undergoing **cardiac surgery for other indication** **Aortic Root Replacement or Repair:** Aortic root diameter of sinuses or ascending aorta >5.5 cm (in patients with bicuspid aortic valve)
Mitral Stenosis Diastolic pressure half time Wilkin Echo Score	i. MVA < 1.5 cm^2 ii. Diastolic pressure half time > 150ms*	**1. PMBC** for **Symptomatic, severe** MS **AND** favorable valve morphology (Echo Score < 8), No clot in LA, NO moderate to severe MR **2. MV Surgery** (Repair = Commissurotomy = MVR) in **severe symptomatic MS** **WITH** No high risk for surgery, Not candidate for PMBC OR Failed PMBC **3.** MV Surgery FOR severe MS (Stage C or D) when other cardiac surgery is done
Mitral Regurgitation	i. Regurgitant volume > 60ml/beat, ii. Regurgitant fraction >50% iii. ERO ≥ 0.4 cm^2 iv. Vena Contracta >0.7 cm v. Central jet MR > 40% LA	1. MV Surgery* ----for---- Symptomatic severe MR AND **EF >30% (**Stage D) 2. MV Surgery* ----for---- **Asymptomatic** sever MR AND LV Dysfunction i.e. EF 30-60% **& /or** LVESD≥40mm (Stage C2) 3. MV Surgery FOR severe MR when other cardiac surgery is done *Repair preferred over MVR whenever possible

Respiratory System Examination Check List (Back)

Pre-Exam	
Stand on right side of patient	
Greetings: Asalam-o-Alaikum	
Introduction	
Consent	
Ask examiner you will like to expose patient fully , have drape , screen for privacy	
Ask Patient Name and call him/her by name instead of calling Aman g , Bibi etc. Meanwhile assess Hoarsness	
Look and Ask if patient is having an IV line (Branula) , if yes , at which site	
Exposure : remove shirt	
Position: sitting , back towards you , hands crossed on both shoulders	
Look for NG , Foley , Drain and its contents Sputum	
Insert Thermometer in axilla and check temperature at end	
Inspection	
Give a general look	
From: back amd then from looking above from scapula	
Posture of patient , comfort ability	
Shape of chest , Symmetry ,	
Ask patient to take a deep breath and B/L moving with respiration	
Visible veins , scars , pulsations radiation mark	
Using accessory muscles : intercostal & subcostal recessions ,	
Supraclavicular fossae: fullness/ indenting	
Look at hands (while crossed on shoulder) for clubbing , cyanosis	
Palpation	
Ask and then Check tenderness , also bone tenderness , also on spine. Look at face of	
Check apical chest movements	
Check chest movements at level of nipple and below	
Chest expansion to be checked in sitting position later at the level of 5th ICS	
Check vocal fremitus apex , intrscapular , 2 points below scapula then lateral	
Check pedal oedema	
Percussion	
Tell patient what and how you will do	
Apex: 3 points and compare each separately , then interscapular , then below scapula and	
Auscultation	
Always compare , first normal than with deep respiration	
Supraclavicular → then inter scapular and then infrascapular.. don't go more than 2 ICS	
Comment on 1. intensity of breath sounds 2. Duration of inspiration 3. Character i.e. vesicular & bronchial 4. Any added sounds : crepitations , rhonchi , rub	

Vocal resonance	
Any other sign : whispering pectorlique , aegophony , coin sign	
Check cervical lymph nodes	
Buffalo hump (due to steroid use)	
Make the patient lie	
Check position of trachea , tracheal tug , FET , apex beat	
Go to foot end , look to confirm findings of back e.g. bulging chest in one side	
Look for chest tube , tap marks , movement of alae nasi	
Perform examination if needed	
Relevant Examination	
Nails : clubbing , cyanosis ,	
Hands: warm , astrerixis , nicotine staining , wasting of hands	
Wrist : check for hypertrophic pulmonary osteoarthropathy	
Pulse : rate & rhythm (a.fib)	
B.P. , Check Temperature	
Brusining of skin , Proximal muscle wasting (by use of steroids in COPD , Asthma)	
Axilla : lymph nodes , Check for acanthosis nigricans	
Eyes: pallor , jaundice (Corpulmonale → congested liver) , Horner syndrome (Ptosis ,	
Face: Butter fly rash in SLE , facial puffiness (pulmonary renal syndromes)	
Mouth : cyanosis , dental hygiene (caries)	
Neck : Thyroid , JVP , non-pulsatile neck veins in SVC obstruction , cervical lymph nodes	
Supraclavicular lymph nodes	
Auscultate for P2 , and heart sounds	
Abdomen : check ascites by shifting dullness (Meig syndrome) , check liver , spleen	
Legs: pedal edema, erythema nodosum (TB)	
Fundoscopy: choroid tubercules , papiloedema in CO2 retention , Brain abscess sec to lung abscess	
End of Exam	
Cover/drape the patient	
Say Thanks	

Respiratory System Examination (Front)

Pre-Exam
Stand on right side of patient
Greetings: Asalam-o-Alaikum
Introduction
Consent
Ask examiner you will like to expose patient fully , have drape , screen for privacy
Ask Patient Name and call him/her by name instead of calling Aman g , Bibi etc. Meanwhile assess Hoarsness
Look and Ask if patient is having an IV line (Branula) , if yes , at which site
Exposure : remove shirt
Position: lying straight on bed with small pillow under head , arms by the side
Look for NG , Foley , Drain and its contents Sputum jar
Insert Thermometer in axilla and check temperature at end
Inspection
From: foot end and from right side of patient
Posture of patient , comfort ability , look at hands to get clue for clubbing (and then consider its DD)
Shape of chest , Symmetry ,
Ask patient to take a deep breath and B/L moving with respiration
Visible veins , scars , pulsations
Using accessory muscles : movement of alae nasi , intercostal & subcostal recessions ,
Supraclavicular fossae: fullness/ indenting
Pursued lips
Ask him to cough . look for epigastric hernia
Count respiratory rate , pattern of breathing
Palpation
Check tenderness , also bone tenderness , Look at face of patient .
Check position of Trachea , Check Apex Beat
Check apical chest movements
Check chest movements at level of nipple and below
Chest expansion to be checked in sitting position later at the level of 5th ICS
Check for crepitations (sub-cutaneous emphysema)
Check vocal fremitus
Percussion
Tell patient what and how you will do
First check upper border of liver
supraclavicular → direct on clavical → then 2-6 ICS by standard method Make inverted V on chest Lateral Percussion : make the patient sit , hands on head and percuss
Auscultation

Always compare , first normal than with deep respiration
Supraclavicular → then 2-6 ICS on front → 4^{-7} ICS laterally
Comment on 1. intensity of breath sounds 2. Duration of inspiration 3. Character i.e. vesicular & bronchial 4. Any added sounds : crepitations , rhonchi , rub
Vocal resonance
Any other sign : whispering pectorlique , aegophony , coin sign
Check apex beat
Make the patient sit
Check tracheal tug , FET
Measure chest expansion by measuring tape
Examine back of chest : at least auscultation
Relevant Examination
Nails : clubbing , cyanosis ,
Hands: warm , astrerixis , nicotine staining , wasting of hands
Wrist : check for hypertrophic pulmonary osteoarthropathy
Pulse : rate & rhythm (a.fib)
B.P. , Check Temperature
Brusining of skin , Proximal muscle wasting (by use of steroids in COPD , Asthma)
Axilla : lymph nodes, Check for acanthosis nigricans
Eyes: pallor , jaundice (Corpulmonale → congested liver) , Horner syndrome (Ptosis , Miosis)
Face: Butter fly rash in SLE , facial puffiness (pulmonary renal syndromes)
Mouth : cyanosis , dental hygiene (caries)
Neck : Thyroid , JVP , non-pulsatile neck veins in SVC obstruction , cervical lymph nodes
Supraclavicular lymph nodes
Auscultate for P2 , and heart sounds
Abdomen : check ascites by shifting dullness (Meig syndrome) , check liver (enlarged tender in abscess)
Legs: pedal edema, erythema nodosum (TB)
Fundoscopy: choroid tubercules , papiloedema in CO2 retention , Brain abscess sec to lung abscess
End of Exam
Cover/drape the patient
Say Thanks

First Cranial nerve (Olfactory)

Pre-Exam
Stand on right side of patient
Greetings: Asalam-o-Alaikum
Which language can you understand better , urdu , Punjabi , Saraiki ?
Introduction
Consent
Ask Patient Name and call him/her by name instead of calling Aman g , Bibi etc.
First Cranial nerve
Ask him 1. Can he smell normally before? **2.** Are you allergic to any thing? **NB:** 1. Check each nostril separately **Perform:** 1. Check with any bedside object e.g. fruits etc. 2. Check selected substances in similar bottles

2nd Cranial Nerve(Optic)

Pre-Exam

Stand on right side of patient

Greetings: Asalam-o-Alaikum

Which language can you understand better , urdu , Punjabi , Saraiki ?

Introduction

Consent

Ask Patient Name and call him/her by name instead of calling Aman g , Bibi etc.

Examination

Perform:

1. **Visual Acuity :** **NB:** Check each eye one by one , DON'T CHECK BINOCULAR ACUITY
   a. Check for any distant object **… Can skip it, far vision is due to refractory problems, not neurological problems**
   b. Check by handheld near vision chart
2. **Visual Field:**
   A. Peripheral Vision
   a. **Binocular :**
      i. Distance should be 1 arm length between you & patient
      ii. You should be at level of patient
      iii. Ask him to look into your eyes
      iv. Ask him to tell you finger of which side is moving when you come inside from both sides . move fingers separately & then both at a time
      v. Test each quadrant separately
   b. **Uniocular :**
      i. Check each eye separately
      ii. **For patient left eye :** ask him to close right eye & close your left eye
      Ask him to look into your eye
      Bring finger from right side upper & lower quadrant
      Then bring finger from left side
      iii. **For patient right eye :** ask him to close left eye & close your right eye
      Ask him to look into your eye
      Bring finger from left side upper & lower quadrant
      Then bring finger from right side upper & lower quadrant

   B. Central Vision:
3. **Colour Vision :** Check by isharah chart
4. **Light Reflex:**
      i. Tell examiner you like to have day/adequate light for this
      ii. Ask patient to look straight on a distant object
      iii. Shine light into one eye and look on reaction of pupil in same eye **(Direct)**
      iv. Shine light into one eye and look on reaction of pupil in OPPOSITE eye **(Consensual)**
      v. **Check for RAPD if light reflex is not normal:**

5. **Accommodation Reflex:**
   Ask him to look at a distant object and then near (his nose, your finger)
   Look for convergence , miosis
6. **Ophthalmoscopy:**
   Pre-requisites:
   1. Consent
   2. Tell examiner you would like to have **Dark room**
   3. Tell examiner you would like to have eyes **Dilated**
   4. **Tell patient** you will come with this instrument , you may come very near , you will not harm him… **Do Not look into light**
   5. Patient right eye , your right eye and use right hand & vice versa

6. **Disc:** comment on **MCC** (Margins , Cup , Colours) **, Vessels , Colour of fundus & any findings**
7. Then ask him to look into the light … to see fovea
8. At the end , say thanks

3rd , 4th , 6th Cranial Nerves

Pre-Exam

Stand on right side of patient

Greetings: Asalam-o-Alaikum

Which language can you understand better , urdu , Punjabi , Saraiki ?

Introduction

Consent

Ask Patient Name and call him/her by name instead of calling Aman g , Bibi etc.

Instruct Patient :

1. Do not move your head. Just move eyes
2. Follow my finger wherever it goes
3. If you see DOUBLE image at any time , inform me

3rd Cranial nerve

1. Look at posture of Head : tilt of head indicates compensatory posture to correct diplopia
2. Look for ptosis
3. Look for position of eyeballs : both should be in center in normal forward gaze
4. Check Pupil size
5. Check Movements in H shape

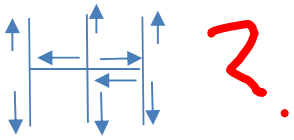

6. Check Light Reflex
7. Check accommodation reflex

4th Cranial Nerve (SO4)



Checking Left 4th Nv

Checking Right 4th Nv

6th nerve (LR 6)

Check both lateral rectus

If there is diplopia in one eye , check it in other eye.

Unilateral diplopia : Neurological

Bilateral diplopia: eye problem

5th Cranial Nerve

Pre-Exam
Stand on right side of patient
Greetings: Asalam-o-Alaikum
Introduction
Consent
Ask Patient Name and call him/her by name instead of calling Aman g , Bibi etc.

Examination of 5th nerve

Motor Part:

1. Ask him to clench his teeth. Check/feel bulk of masseters
2. Ask him to clench his teeth. Check/feel bulk of temporalis
3. Ask him to move jaw from side to side and then against resistance
4. Jaw Jerk do only if other positive findings there

Sensory Part:

1. Check Touch , Pain , Temperature in each division of 5th Nerve separately and compare
2. Corneal reflex
3. Conjuctival reflex

7th Cranial Nerve

Pre-Exam
Stand on right side of patient
Greetings: Asalam-o-Alaikum
Introduction
Consent
Ask Patient Name and call him/her by name instead of calling Aman g , Bibi etc.
Examination
1. Check hyperacusis 2. Frowning : ask him to look at ceiling 3. Ask him to close eyes forcefully and try to open 1 4. Look for dribbling of saliva / patient taking tissue to clean saliva 2 5. See nasolabial folds 6. Ask him to show teeth and comment on deviation of angle of mouth 7. Ask him to smile 8. Ask him fill cheeks with air and then gently tap 9. Check corneal & conjuctival reflex 10. Tell examiner you will like to check whistling , taste over anterior 2/3 of tongue

9th, 10th, 11th , 12th Cranial Nerve

Pre-Exam
Stand on right side of patient
Greetings: Asalam-o-Alaikum
Introduction
Consent
Ask Patient Name and call him/her by name instead of calling Aman g , Bibi etc.
Examination of 9th nerve
1. Is NG in place i.e. gag not intact 2. Check gag reflex. Touch each side of pharynx separately 3. Palatal Reflex: touch soft palate with blunt probe, ask patient about felt or not (sensory) , check movements of soft palate 4. Check taste over posterior 1/3 of tongue 5. Carotid massage and observe associated slowing of heart rate
Examination of 10th nerve
1. Nasal twang in speech : Ask him to say egg .. he will say eng 2. See uvula . is it central? 3. Aah test: ask him to say aah. See if uvula elevates and posterior pharyngeal wall constricts 4. Ask him to cough 5. Check Gag reflex. Touch each side of pharynx separately 6. Check palatal reflex 7. Indirect laryngoscopy 8. Carotid massage
Examination of 11th nerve
1. Look at bulk , wasting , atrophy of both muscles 2. Look for involuntary movemnts 3. Test each sternocleidomastoid separately. Feel the opposite muscle 4. Ask him to move head down normal and than against resistance 5. Ask him to shrug his shoulders for trapezius
Examination of 12th nerve
1. Examine the tongue with in oral cavity for fasciulations , wasting 2. Ask him to protrude. Look for deviation. 3. Ask him to move tongue on each side 4. Move tongue on each side against cheek. Check for resistance

Tongue(12th CN) and Jaw (5th CN) never lie. i.e. if tongue deviated to right , lesion is in right 12th CN

Examine ALL cranial Nerves

Pre-Exam
Sit on chair OR stand on right side of patient… Sit at level with patient
Greetings: Asalam-o-Alaikum
Introduction
Consent: I shall examine your face
Ask Patient Name and call him/her by name instead of calling Aman g, Bibi etc. **Meanwhile assess Hoarseness**
Inspect
Obvious findings: ptosis, proptosis, loss of nasolabial fold, facial deviation , drooling of saliva, using tissues again & again . NG in place,
Olfactory Nerve
1. Do you have any problem with smell? 2. Avoid detailed testing. inform examiner at the end I want to do it
2nd,3rd,4th,6th
1. Look at posture of Head: tilt of head indicates compensatory posture to correct diplopia 2. Look for ptosis 3. Look for position of eyeballs: both should be in center in normal forward gaze 4. Check Visual Acuity 5. Check Colour Vision 6. Light Reflex (2nd, 3rd) 7. Accommodation Reflex (2nd, 3rd) 8. Check Movements in H shape 9. Check Field of Vision 10. Fundoscopy: perform at the end if time permits or inform examiner
5th CN
Motor Part: 1. Ask him to clench his teeth. Check/feel bulk of masseters 2. Ask him to clench his teeth. Check/feel bulk of temporalis 3. Ask him to move jaw from side to side and then against resistance 4. Jaw Jerk (PERFORM ONLY if any +ve finding in motor exam) **Sensory Part:** 1. Check Touch, Pain, Temperature in each division of 5th Nerve separately and compare 2. Corneal reflex 3. Conjunctival reflex avoid these reflexes, uncomfortable for patient

7th , 8TH

1. Check hyperacusis (7th) or Decreased Hearing (8th) … fingers tapping on both sides, then close one side with finger and test other side … and vice versa
2. Frowning : ask him to look at ceiling …. ماتھے پر بل ڈالیں
3. Ask him to close eyes forcefully and try to open
4. Look for dribbling of saliva / patient taking tissue to clean saliva
5. See nasolabial folds
6. Ask him to show teeth and comment on deviation of angle of mouth
7. Ask him to smile
8. Ask him fill cheeks with air and then gently tap
9. Check corneal & conjuctival reflex (Avoid)

Tell examiner you will like to check whistling, taste over anterior 2/3 of tongue

9th,10th

1. Is NG in place i.e. gag not intact
2. Nasal twang in speech : Ask him to say egg .. he will say eng
    a. **OPNE MOUTH….**
3. See uvula . is it central?
4. Aah test: ask him to say aah. See if uvula elevates and posterior pharyngeal wall constricts
5. Ask him to cough
6. Check gag reflex. Touch each side of pharynx separately **[ASK EXAMINER before proceeding)**
7. Palatal Reflex: touch soft palate with blunt probe, ask patient about felt or not (sensory) , check movements of soft palate
8. Check taste over posterior 1/3 of tongue (omit)
9. Carotid massage and observe associated slowing of heart rate (omit)
10. Indirect laryngoscopy (Omit)
11. Carotid massage (Omit)

Examination of 11th nerve

1. Look at bulk , wasting , atrophy of both muscles
2. Look for involuntary movements
3. Test each sternocleidomastoid separately. Feel the opposite muscle
4. Ask him to move head down normal and than against resistance
5. Ask him to shrug his shoulders for trapezius

Examination of 12th nerve

1. Examine the tongue with in oral cavity for fasciulations, wasting
2. Ask him to protrude. Look for deviation.
3. Ask him to move tongue on each side
4. Move tongue on each side against cheek. Check for resistance

TELL EXAMINER I would like to complete Exam by

1. Ding Fundoscopy 2. Checking taste 3. Checking smell in detail
4. I omitted corneal, conjunctival, gag reflex for patient comfort

motor

Examine ALL cranial Nerves

Pre-Exam
Sit on chair OR stand on right side of patient… Sit at level with patient
Greetings: Asalam-o-Alaikum
Introduction
Consent: I shall examine your face
Ask Patient Name and call him/her by name instead of calling Aman g, Bibi etc. **Meanwhile assess Hoarseness**
Inspect
Obvious findings: ptosis, proptosis, loss of nasolabial fold, facial deviation , drooling of saliva, using tissues again & again . NG in place,
2nd,3rd,4th,6th
1. Look at posture of Head: tilt of head indicates compensatory posture to correct diplopia 2. Look for ptosis 3. Look for position of eyeballs: both should be in center in normal forward gaze 4. Light Reflex (3rd) 5. Accommodation Reflex (2nd, 3rd) 6. Check Movements in H shape
5th CN
Motor Part: 1. Ask him to clench his teeth. Check/feel bulk of masseters 2. Ask him to clench his teeth. Check/feel bulk of temporalis 3. Ask him to move jaw from side to side and then against resistance 4. Jaw Jerk (PERFORM ONLY if any +ve finding in motor exam)
7th , 8TH
1. Check hyperacusis (7th) or Decreased Hearing (8th) … fingers tapping on both sides, then close one side with finger and test other side … and vice versa 2. Frowning : ask him to look at ceiling …. ماتھے پر بل ڈالیں 3. Ask him to close eyes forcefully and try to open 4. Look for dribbling of saliva / patient taking tissue to clean saliva 5. See nasolabial folds 6. Ask him to show teeth and comment on deviation of angle of mouth 7. Ask him to smile 8. Ask him fill cheeks with air and then gently tap 9. Check corneal & conjuctival reflex (Avoid) Tell examiner you will like to check <u>whistling</u>,

9th,10th

1. Is NG in place i.e. gag not intact
2. Nasal twang in speech : Ask him to say egg .. he will say eng
    a. **OPNE MOUTH….**
3. See uvula . is it central?
4. Aah test: ask him to say aah. See if uvula elevates and posterior pharyngeal wall constricts
5. Ask him to cough
6. Check gag reflex. Touch each side of pharynx separately **[ASK EXAMINER before proceeding)**
7. Palatal Reflex: touch soft palate with blunt probe, ask patient about felt or not (sensory) , check movements of soft palate
8. Indirect laryngoscopy (Omit)

Examination of 11th nerve

1. Look at bulk , wasting , atrophy of both muscles
2. Look for involuntary movements
3. Test each sternocleidomastoid separately. Feel the opposite muscle
4. Ask him to move head down normal and than against resistance
5. Ask him to shrug his shoulders for trapezius

Examination of 12th nerve

1. Examine the tongue with in oral cavity for fasciulations, wasting
2. Ask him to protrude. Look for deviation.
3. Ask him to move tongue on each side
4. Move tongue on each side against cheek. Check for resistance

TELL EXAMINER about what relevant examination you will like to do

e.g. other cranial nerves , or check sensory component of cranial nerves , limb exam

Examine ALL cranial Nerves sensory

Pre-Exam
Sit on chair OR stand on right side of patient… Sit at level with patient
Greetings: Asalam-o-Alaikum
Introduction
Consent: I shall examine your face
Ask Patient Name and call him/her by name instead of calling Aman g, Bibi etc. **Meanwhile assess Hoarseness**
Inspect
Obvious findings: ptosis, proptosis, loss of nasolabial fold, facial deviation , drooling of saliva, using tissues again & again . NG in place,
Olfactory Nerve
1. Do you have any problem with smell? 2. Avoid detailed testing. inform examiner at the end I want to do it
2nd,3rd,4th,6th
1. Check Visual Acuity 2. Check Colour Vision 3. Light Reflex (2nd, 3rd) 4. Accommodation Reflex (2nd, 3rd) 5. Check Field of Vision 6. Fundoscopy: perform at the end if time permits or inform examiner
5th CN
Sensory Part: 1. Check Touch, Pain, Temperature in each division of 5th Nerve separately and compare 2. Corneal reflex 3. Conjunctival reflex avoid these reflexes, uncomfortable for patient
7th , 8TH
1. Check Decreased Hearing (8th) … fingers tapping on both sides, then close one side with finger and test other side … and vice versa 2. Check corneal & conjuctival reflex (Avoid) 3. Tell examiner you will like to check taste over anterior 2/3 of tongue
9th,10th
1. Check gag reflex. Touch each side of pharynx separately **[ASK EXAMINER before proceeding)** 2. Palatal Reflex: touch soft palate with blunt probe, ask patient about felt or not (sensory) , check movements of soft palate 3. Check taste over posterior 1/3 of tongue (omit) 4. Carotid massage and observe associated slowing of heart rate (omit) 5. Indirect laryngoscopy (Omit) 6. Carotid massage (Omit)
TELL EXAMINER I would like to complete Exam by Doing relevant exam i.e. motor component of cranial nerves, limb exam etc

Cerebellar Examination Check List

Action	
Pre-Exam	
Stand on right side of patient	
Greetings: Asalam-o-Alaikum	
Introduction	
Consent	Assess speech
Ask Patient Name and call him/her by name instead of calling Aman g , Bibi etc.	
Position: if supine , ask to sit and fold arms	Truncal Ataxia
Examination	
Look **posture** – in unilateral lesion , patient droops down toward affected side	
Ask patient if he is having weakness of any limb/side . Cerebellar signs cant be checked if power is less than +4/5	
1. Nystagmus in Eyes: Go so much that canthus is buried , not farther than that Check both horizontal & vertical nystagmus	
2. Scanning Speech : Talk to him , ask his complete address or ask to say "Constantinople" in urdu	
3. Upper Limbs: 1. **Hypotonia** : check only at elbow 2. **Intention Tremors , Dysmetria i.e. past-pointing** : perform finger-nose-finger test 3. **Dysdiadochokinesia** : Ask him to clap hands alternatively with palm and dorsum 4. **Rebound phenomenon** : Ask to flex elbow against resistance , can hit face (You can tell examiner I did not performed it as there is chance of injury to patient) or press against hands straight forward and then suddenly release	
4. Lower Limbs : 1. **Pendulous Knee jerk** 2. **Make him stand :** patient sways towards affected side 3. **Broad based Gait: ask him to walk** 4. **Tandem Walking:**	
5. Check VII & VIII Cranial Nerves	**Shawanoma**
6. Auscultate Cerebelli	**?**
7. If unilateral signs, auscultate heart	**Source of thrombus**
If Command is to check cerebellar signs in lower limb only , then check 1. Tone 2. Heel-shin-heel test 3. Toe-finger-Toe test 4. Rebound phenomenon : ask him to raise leg against resistance and then release 5. Make him stand 6. Gait 7. Tandem walking 8. Pendulous knee jerk	

Others By Dr. Zaman …. Reason ?

Pupillary reflex in eyes

Oral (Ginivae) phenytoin

Neck (Thyroid , Lymph Nodes)

Pes Cavus (Foot)

Motor System of Lower Limb

Pre-Exam

Stand on right side of patient

Greetings: Asalam-o-Alaikum

Introduction

Consent

Ask Patient Name and call him/her by name instead of calling Aman g , Bibi etc.

Exposure

Ask if pain in any part of body

Examination (WIP-TPRC)

1. **Look** for
   i. Bulk & Wasting . Measure if required
   ii. Involuntary movements
   iii. Abnormal Posturing
2. Look for **fasciulations.** Tap and observe for 10 sec
3. **Tone:**
   i. Rotate each leg separately while its on bed. Look at movements of feet
   ii. Flex Legs at knee joint . lift by putting hands below lower thigh
   iii. Flex both legs at knee joint after making them fully straight
   iv. Check tone at ankle joint

DO NOT comment on cog-wheel in lower limb as rotatory movement is required for that

4. **Power:**
   i. Ask him to raise legs. If cant lift both legs , ask him to raise arms (to see quadriplegia or hemiplegia) check power in feet even if he cant raise leg
   ii. If can lift legs , check power at each joint
      a. Hip : Flexion , extension , Abduction , adduction
      b. Knee: Flexion , extension
      c. Ankle: flexion, extension
5. **Reflexes: Re-ensure patient hammer will not harm you.** If reflex not elicited , perform **Jendrassik maneuver**
   i. Knee jerk
   ii. Ankle jerk
6. **Plantars : Tell him what you are going to do. Ask for pain in toe**

If not elicited , *Gordon's sign , Oppenheim's sign , Chaddock signs*

7. **Clonus: Check ankle clonus & patellar clonus**

   Check clonus if plantars upgoing or tone is increased
8. Coordination :
   Perform Heel Shin Heel test
9. Gait:
10. Ask him to sit and then stand without support

Relevant Examination (Modify case to case)

1. **Is folley in place?** Sphincters not intact
2. **Paraplegia :** check pain . locate sensory level
3. **Quadreplegia :** check pain in both upper & lower limb. And get sensory level
4. Hemiplegia: check upper limb motor system , facial nerve , NG,

Motor System of Upper Limb

Pre-Exam

Stand on right side of patient

Greetings: Asalam-o-Alaikum

Introduction

Consent

Ask Patient Name and call him/her by name instead of calling Aman g , Bibi etc.

Exposure

Ask if pain in any part of body

Examination (WIP-TPRC)

1. **Look** for
   - i. Bulk & Wasting . Measure if required
   - ii. Involuntary movements
   - iii. Abnormal Posturing
2. Look for **fasciulations.** Tap and observe for 10 sec
3. **Tone:**
   - i. Wrist Joint : for cogwheel rigidity
   - ii. Elbow Joint : for spasticity , lead pipe rigidity extend elbow from fully flexed position
4. **Power: Fix proximal joint while checking power at joint distal to that**
   - **i.** Ask him to raise both arms
   - **ii.** Check power as :
     a. **Fingers :** flexors , extensors ; fix wrist joint
     b. **Wrist:** flexors , extensors **; hold forearm** close fist and then move it
     c. **Elbow:** flexors , extensors
     d. **Shoulder :** abduction , adduction (Hold below elbow and ask to move out & in)

   Normal & against resistance
5. **Reflexes: Re-ensure patient hammer will not harm you.** If reflex not elicited , perform **Jendrassik maneuver**
   - i. Biceps
   - ii. Triceps
   - iii. Brachioradialis
6. **Hoffaman Sign:**
7. **Coordination :** finger-nose-finger test

Relevant Examination (Modify case to case)

1. **Is NG in place?** gag not intact
2. **Check sensory level**

Gait

Step	Command	
1	Make the patient stand	Stroke patient will not be able to stand
2	Ask him to walk normally for few feet	Base of gait , gross cerebellar deficit , parkinsonian gait
3	AND turn back	Parkinsonism difficulty in turning back
4	Come back with Tandem Walking	Suttle cerebellar deficit
5	Ask him to close feet , then with hands in front	Cerebellar atxia
6	Step 5 + close eyes	Romberg's test… posterior column deficit
7	Sit and get up without support	Proximal wekaness

Motor Neuron Disease

Command: **Examine the lower limb and do the relevant**

	PRE-EXAM	
	Stand on right side of patient	
1	Greetings: Asalam-o-Alaikum, Shake Hand	
	Introduction	
	Ask Patient Name and call him/her by name instead of calling Aman g , Bibi etc.	**i. Assess speech:** Spastic (Dysarthria, Nasal) ii. Note any facial weakness
	Ask which language can he/she understand better?	
	Consent	
	Position: lying flat	
	Ask if patient is having an IV line (Branula), if yes, at which site	
	Look for NG, Foley, Drain and its contents	
	Examination Proper	
2	**Motor System:** 1. Look for: i. Bulk & Wasting. ii. Involuntary movements iii. Abnormal Posturing 2. Look for fasciulations. Tap and observe for 10 sec 3. Tone: 4. Power: 5. Reflexes: i. Knee jerk ii. Ankle jerk 6. Plantars: 7. Clonus: Check ankle clonus & patellar clonus Check clonus if plantars upgoing or tone is increased 8. Coordination:	Mixed lower and upper motor neuron signs e.g. Fasciulations +ve Hypotonia Some reflexes +++, some + wasting
3	**Sensory System of Lower Limb:** i. Pin prick ii. Vibration	intact
4	Upper Limbs: Look: specially at hands Power Reflexes Hoffman's sign	Loss of bulk specially ➢ between thumb and index ➢ eminences
5	Assess facial weakness: i. wrinkling of forehead ii. nasolabial fold iii. smile iv. show teeth	
6	Open Mouth: i. Fasciculations in tongue ii. Tongue atrophy iii. Protrude tongue iv. See uvula v. Tell examiner I will like to check Gag reflex	Weakness
7	Check extraocular movements (Grossly)	Intact
8	Check chest expansion	If no time, tell examiner
9	Sir I would like to examine for i. Chest expansion ii. Cognitive functions	?

Horner Syndrome

Command: Examine the eyes and do the relevant

	Action	Significance
	Pre-Exam	
	Stand on right side of patient	
	Greetings: Asalam-o-Alaikum	
	Introduction	
	Consent	Assess speech
	Ask Patient Name and call him/her by name instead of calling Aman g , Bibi etc.	
	Position: if supine, ask to sit	
	Examination	
1	**Examine Eyes:** I. Look for Enophthalmos II. Ptosis (Marginal Reflex Distance MRD) III. Pupillary right reflex IV. Ask him to look upward V. Check Extraocular movements	 Unable to look R°Brainstem Stroke
2	Touch face / arms/ shoulder for sweating	Anhydrosis
3	Look at neck i. Scars ii. Acanthosis Nigricans iii. Swellings/ lumps iv. Palpate Lymph Nodes v. Palpate Thyroid vi. Palpate carotid	 ?
4	Upper Chest i. Tenderness ii. Percuss and auscultate	
5	Hands: i. Clubbing ii. Nicotine staining iii. Wasting of small muscles of hands iv. Check grip v. Check sensations vi. Pulse ….Examine for cervical ribs (raise hand and check for decreasing volume)	
6	Arms: i. Acanthosis Nigricans ii. Axillary Lymph Nodes	
7	Check for Plantars	Multiple Sclerosis
8	Fundoscopy	

Speech Examination Check List

Action	Performed	
	Yes	**No**
Pre-Exam		
Stand on right side of patient		
Greetings: Asalam-o-Alaikum		
Introduction		
Consent		
Ask Patient Name and call him/her by name instead of calling Aman g , Bibi etc.		
Ask 4 things before proceeding for exam		
1. What language do you speak and understand? (first language)		
2. Are you right or left handed? (to know dominant lobe)		
3. How much are you literate?		
4. Is any part of your body weak i.e. right or left sided paralysis? (e.g. if you ask him to raise left hand and he is paralyzed on that side)		
Speech Examination		
1. Start conversation with patient for 1-2 minutes and assess for **a. Rate** **b. Fluency** **c. Is speech sensible?** Does he use words correctly **Command:** What is your name , complete address .how will you go home from this place? What do you do? What have you done since morning? **And continue conversation**		
2. Check Comprehension i.e. understanding (DO NOT give visual clues) a. Give command with yes or no answer? Is this a pen? b. Simple command Close your eyes OR raise your left arm OR open your mouth c. Complex Commands: Give him piece of paper and ask to Pick paper from bed , fold it and put it in your left pocket (cross midline) OR With your right hand touch your nose and then your left ear.'		
3. Assess Naming can restrict to a **a.** Ask him to name familiar objects that are to hand e.g. watch , keys,pen b. Tell me names of all animals you know (Normal: 18-22 in 1 min) c. Tell all the words beginning from alphabet A or B		
4. Repetition: Ask him to repeat اگر مگر لیکن یا چونکہ چنانچہ اگرچہ		
5. Reading : Check there is no visual impairment a. Ask him to read a sentence b. Give him a written command to follow e.g. Mr. Asghar : Close your eyes		
6. Writing: Ask him to write a sentence		
7. Calculation: Adjust to premorbid expectations. a. Ask him 100-7 = _____ and so on b. Ask him 3+3=_____ , +3 =____ and so on c. Ask him complex commands 2 + 3; 7 + 12; 21 − 9; 4 × 7; 36 ÷ 9 etc		

Parkinsonism

Command: **Examine the face and do the relevant**

	PRE-EXAM	
	Stand on right side of patient	
1	Greetings: Asalam-o-Alaikum, Shake Hand	Cog-wheel rigidity
	Introduction	
2	Ask Patient Name and call him/her by name instead of calling Aman g , Bibi etc.	**Assess speech:** i. Monotonous ii. Low volume iii. Tremulous
	Ask which language can he/she understand better?	
	Consent	
	Position: sitting	
	Ask if patient is having an IV line (Branula), if yes, at which site	
	Look for NG, Foley, Drain and its contents	
	Examination Proper	
3	Step Back, Look at face	Mask-like Expressionless
4	Put hands in lap in semi-prone position	Resting Pill rolling tremors
5	Close eyes gently	Blepharoclonus - tremors
6	Glabellar tap from behind or side	Myerson's sign
7	Again shake hand	Cog-wheel rigidity
8	Flex elbow	Lead pipe rigidity
9	Ask patient to rapidly and repeatedly oppose thumb and index finger … test both hands	
10	Stand up	bradykinesia
11	Walk … assess gait	i. Freezing – difficulty in initiating movement ii. Stooped posture iii. Narrow based gait iv. Hesitant shuffling gait v. Decreased arm swing vi. Difficulty in stopping and turning rapidly back
12	**Retropulsion / Pull Test:** I am going to pull you from hip. Keep your balance. you can take steps back if needed	+ve = Postural Instability +ve if Person takes ≥3 steps Or Falls without taking a step
13	Ask patient to sit and **examine Eyes** for i. Vertical gaze palsy ii. Horizontal nystagmus (cerebellar)	
14	Perform Finger **Nose Test**	Dysdiadochokinesia
15	Check hand writing	micrographia
15	Ask patient to lie and check **Plantars**	
16	Sir I would like to check i. Blood Pressure for orthostatic hypotension ii. Mini Mental State Exam iii. For seborrhea (sweating) iv. Fundoscopy Retinitis Pigmentosa	 Shy-Drager syndrome For dementia ? in Hallervorden- Spatz Disease / Pantothenate kinase-associated neurodegeneration

Causes of Proximal Myopathy:

Endocrine	Acromegaly Hyperthyroidism, Hypothyroidism Hyper-parathyroidsm, hypo-parathyroidsm (osteomalacia) Cushing Syndrome
Rheumatologic	Dermatomyositis, Polymyositis, Inclusion body myositis RA, SLE
NMJ Dx	Myasthenia Gravis, Lambert Eaten Syndrome
Drugs	Corticosteroids, Statins, fibrates Zidovudine, alcohol, amiodarone
Metabolic	Enzyme deficiency, mitochondrial disease
Muscular dystrophy	Limb girdle muscular dystrophy, Fascio-scapulo-humeral dystrophy

Proximal Myopathy Examination

Command: Examine the lower limbs neurologically and do the relevant

Neurological Examination	
Inspection	Symmetric wasting
Palpation	Check tenderness
Bulk, Tone,	
Power	Check for repetitive testing (MG. Lambert eaten)
, Reflexes, Plantars	+++ in hyperthyroidism, + or – in hypothyroidism with delayed relaxation
Coordination,	
Gait	Waddling gait
Gower Sign	
Relevant Examination to find Etiology	
Look	i. Moon face ii. Buffalo hump iii. Visible thyroid swelling
Hands	i. Sweating / coarse skin (in hyper or hypo thyroidism) ii. Signs of acromegaly iii. Tremors iv. Gottron Papules v. Paper Thin Skin
Pulse	Hyperthyroidism
B.P.	Cushing Syndrome, Thyrotoxicosis , hypothyroidism
Hair	Coarse in hypothyroidism
Face	Heliotrope rash V sign Thyroid eye disease Cataract in Cushing's Chvostek Sign
Sternum	Bone tenderness IN osteomalacia
Go on back	Palpate thyroid Auscultate chest – ronchi of asthma for which might be taking steroids , small cell CA
Legs	Non pitting edema in hypothyrodism